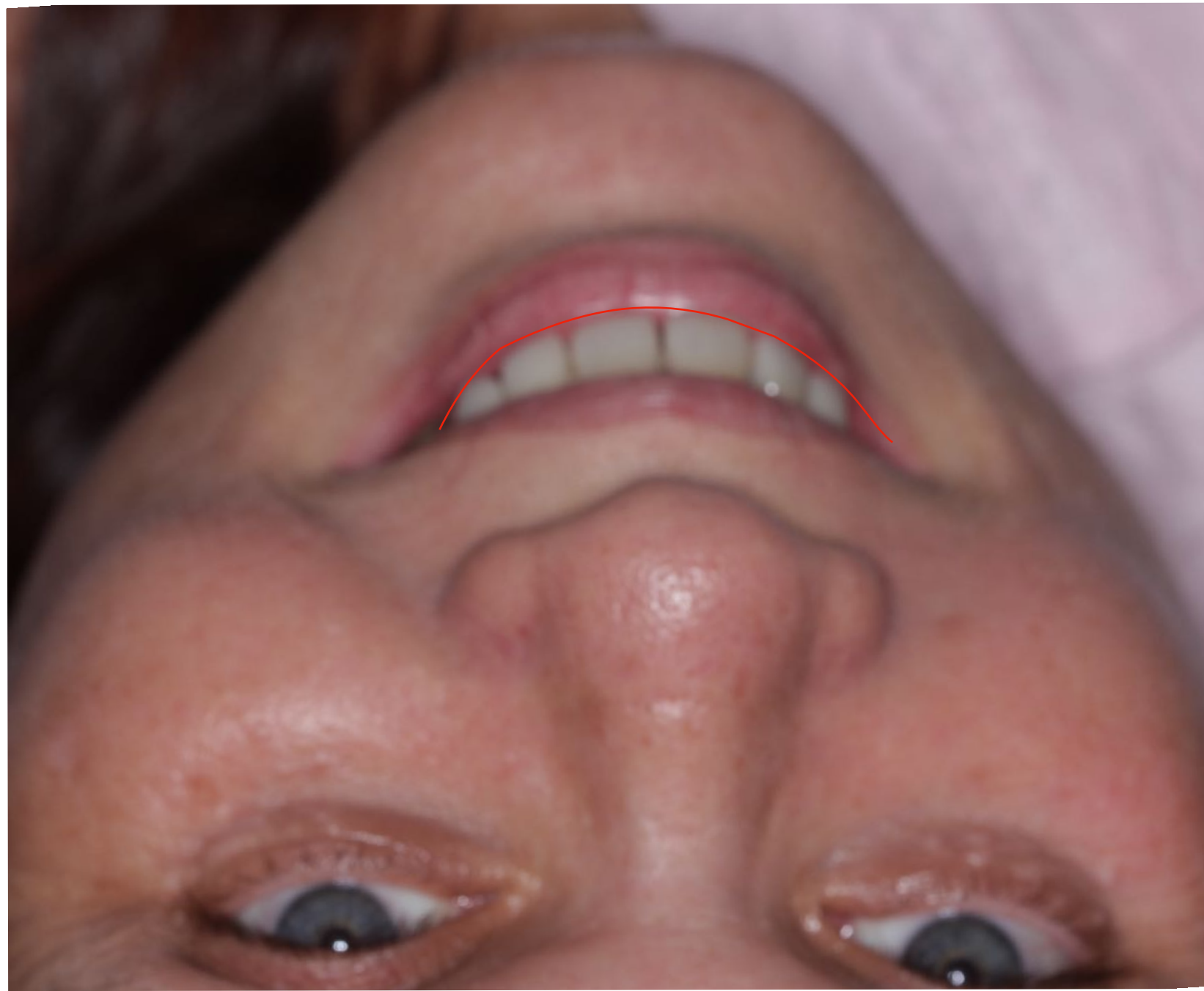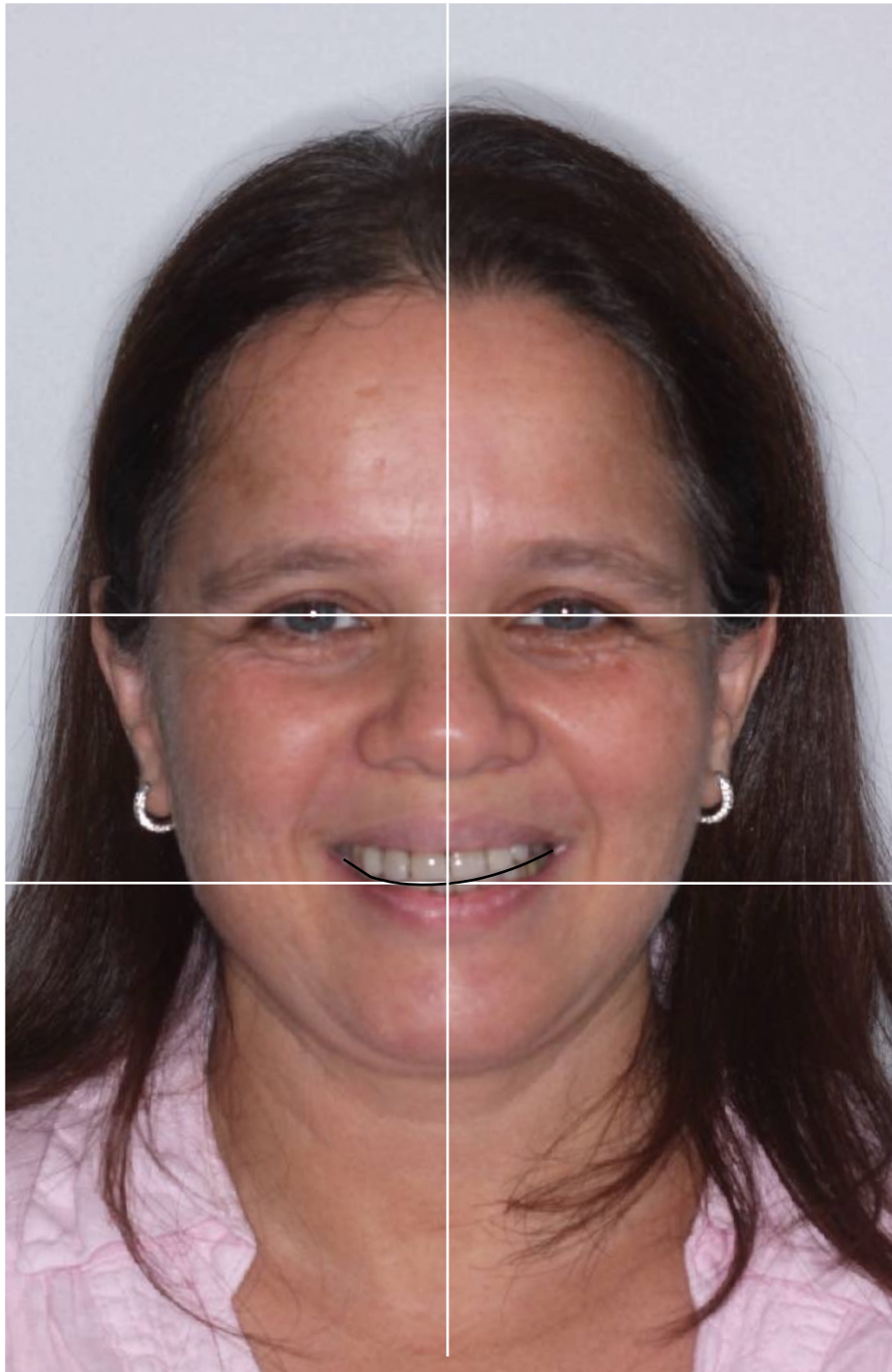


**Dipti Gandhi**



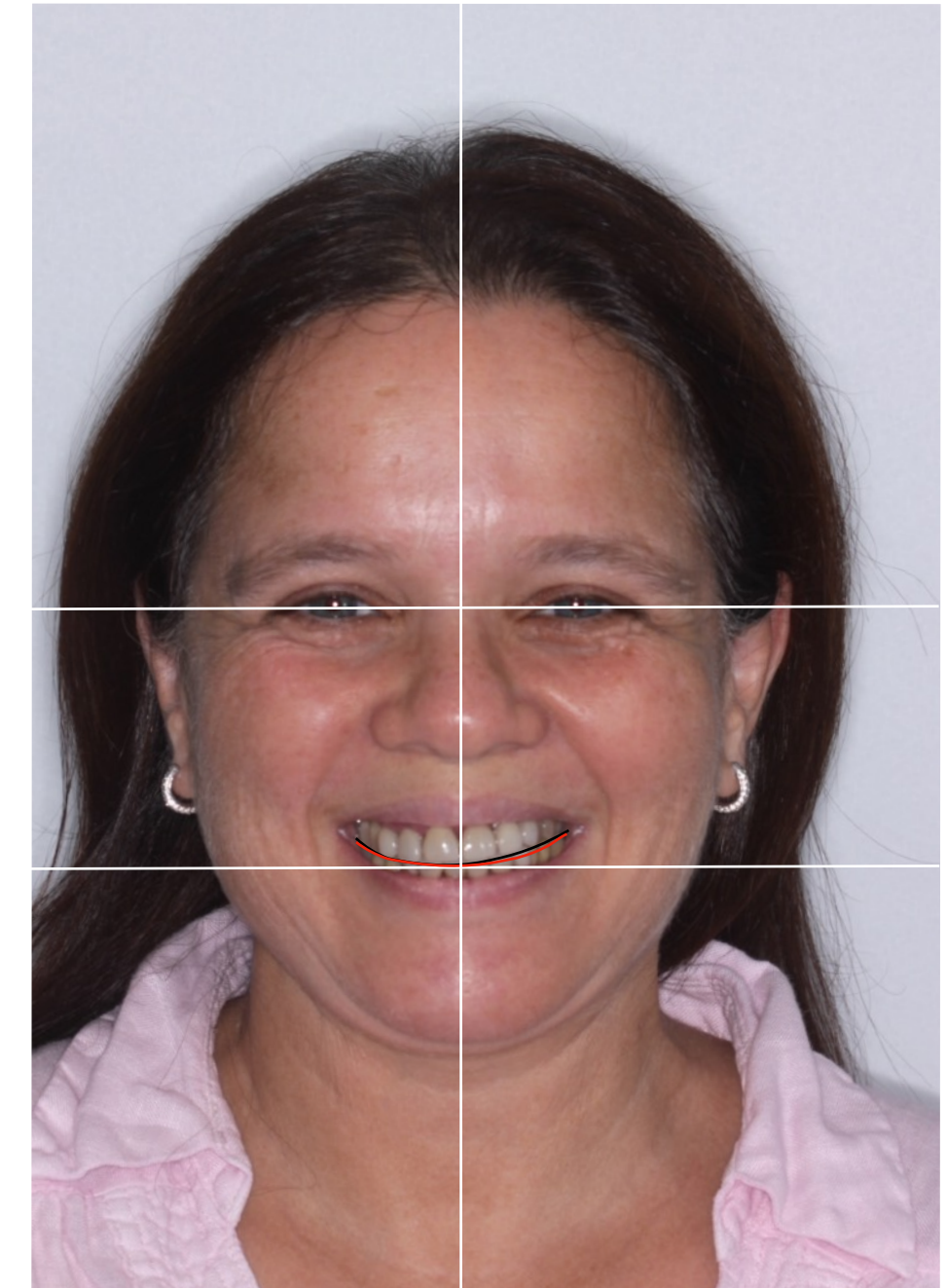




the right side 13,12,11, the incisal plane is lower more occlusal, and there is more gingival display

the left side 21,22,23 the incisal plane is moving up gingival and less gingival display

black is plane of current edge  
red is proposed incisal plane



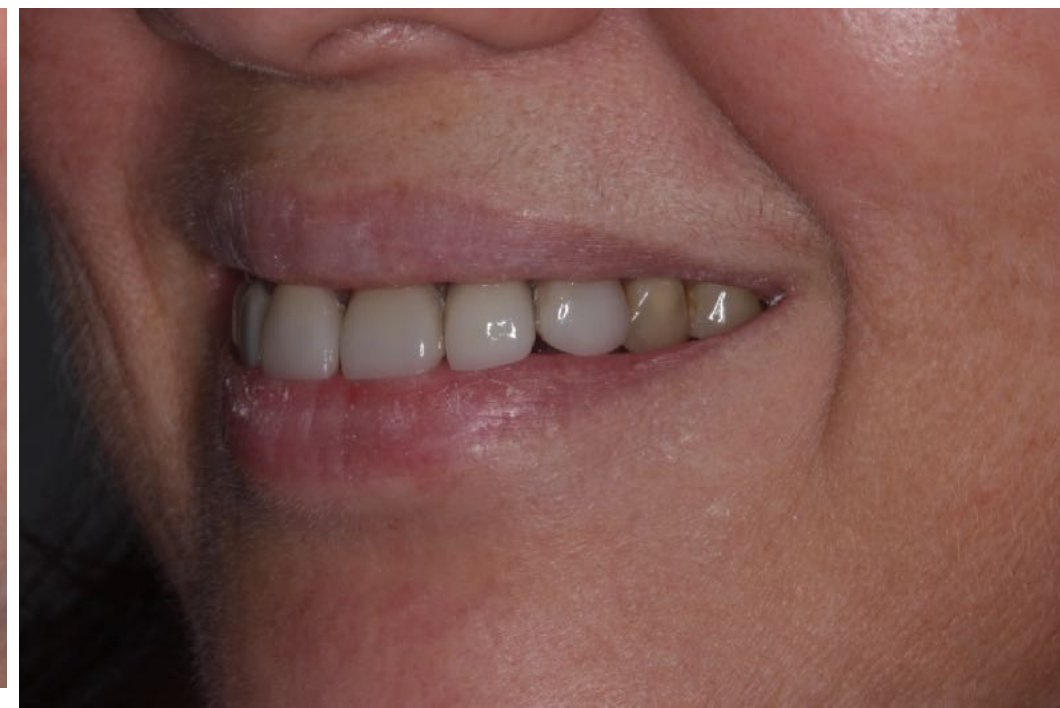
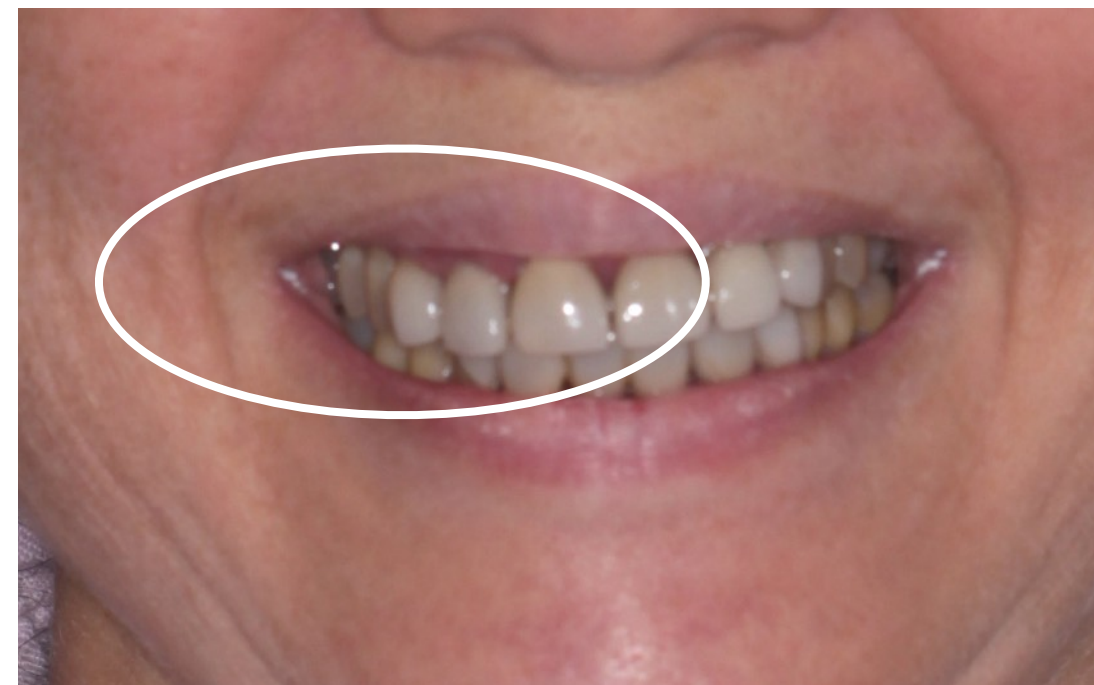
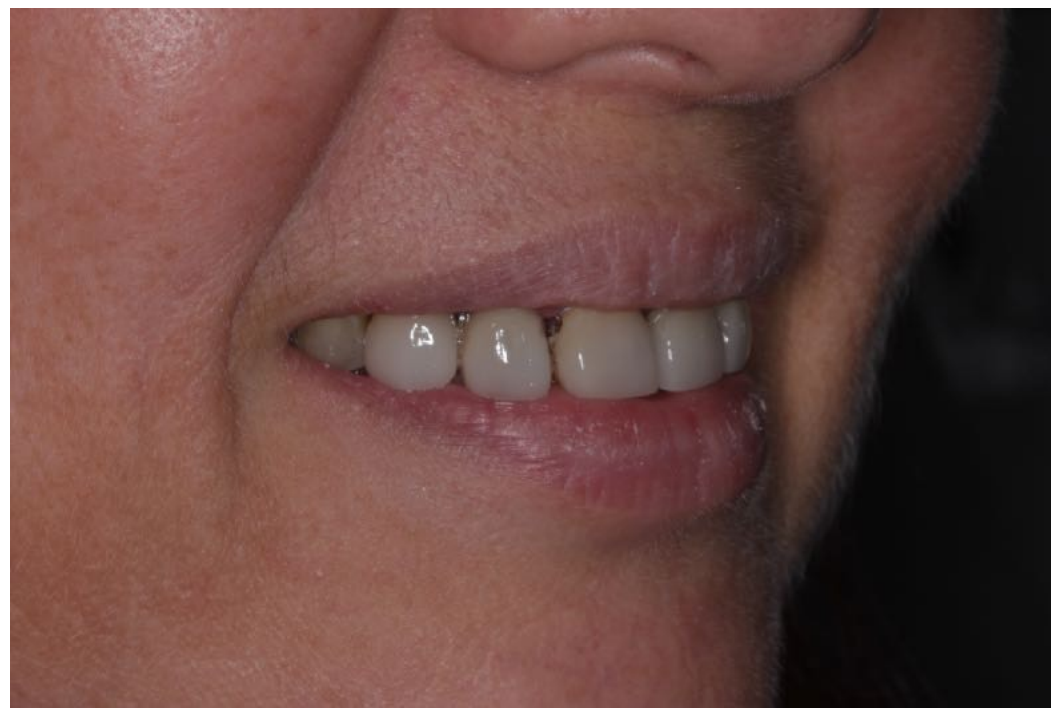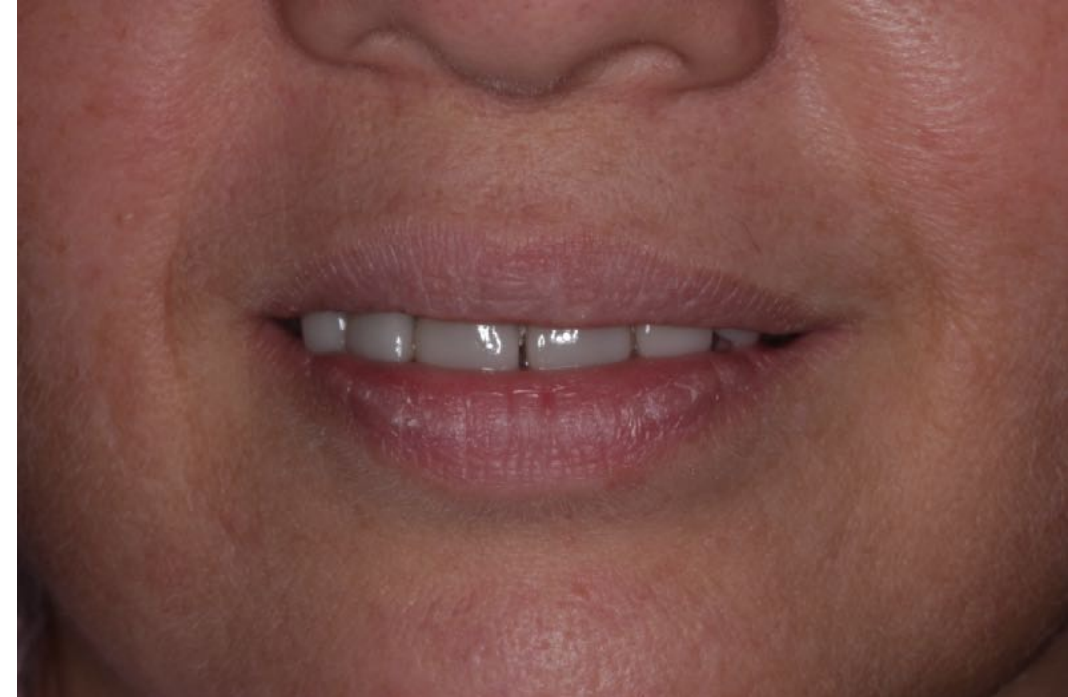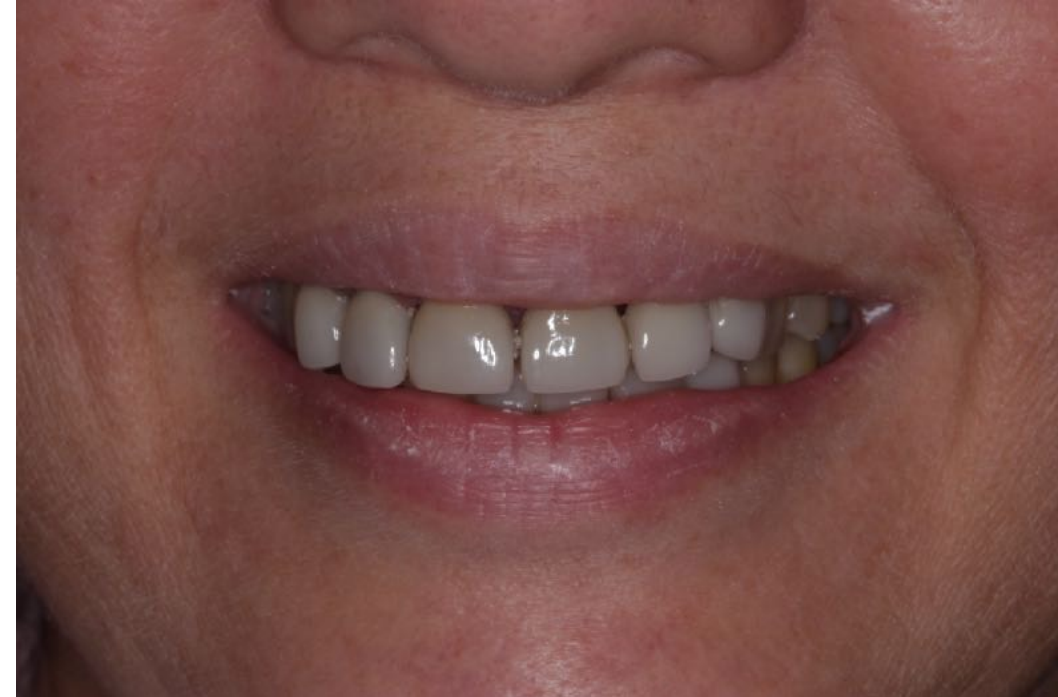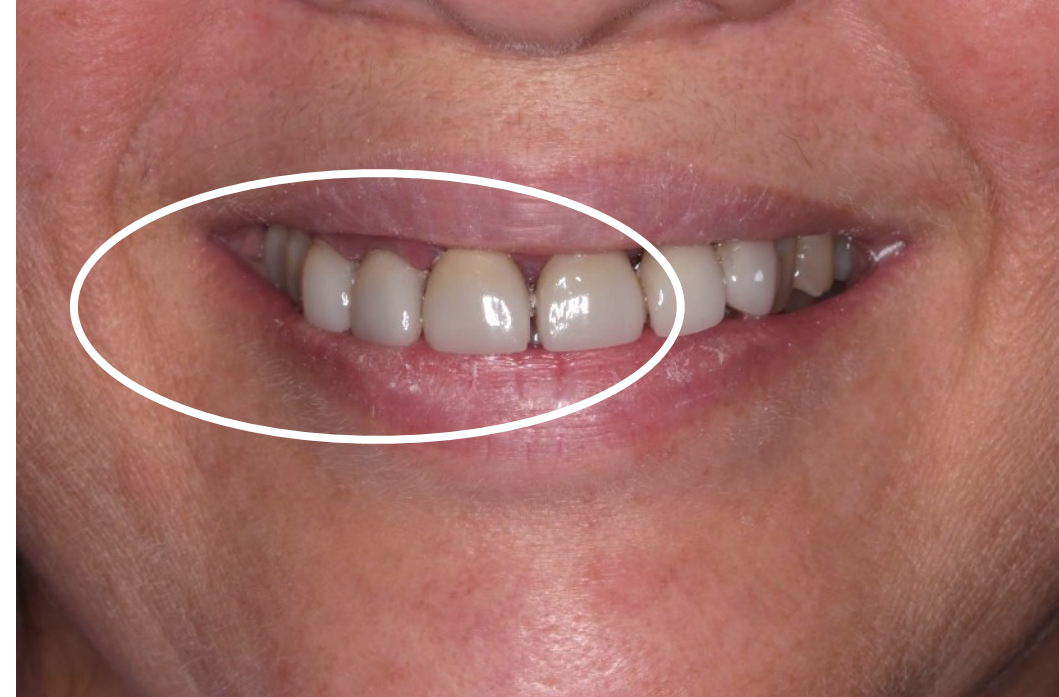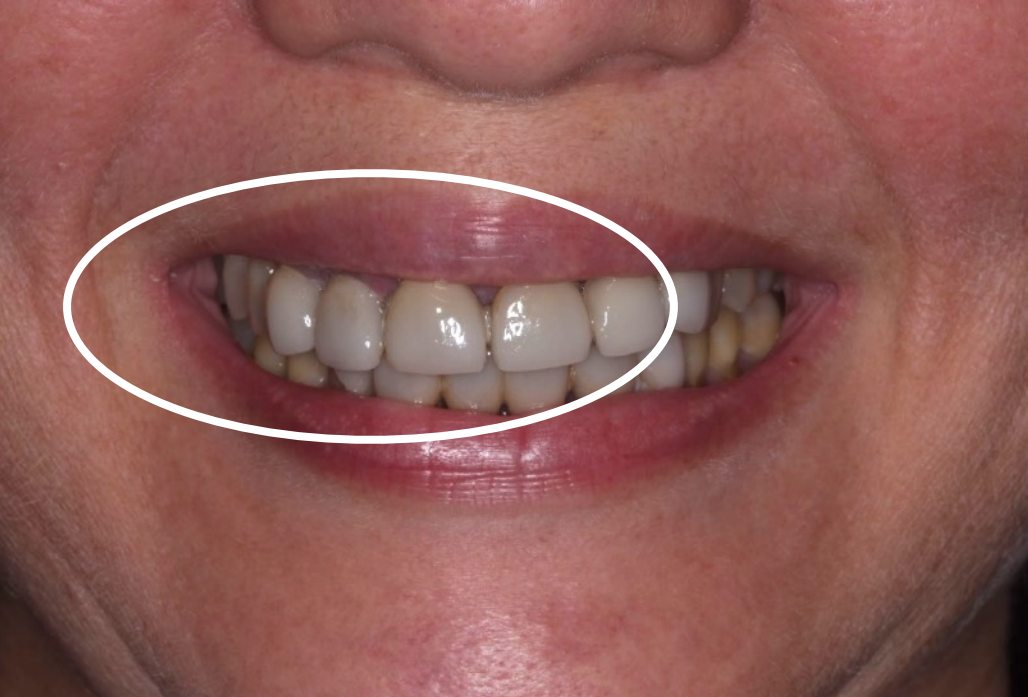the right side 13,12,11, the incisal plane is lower more occlusal, and there is more gingival display

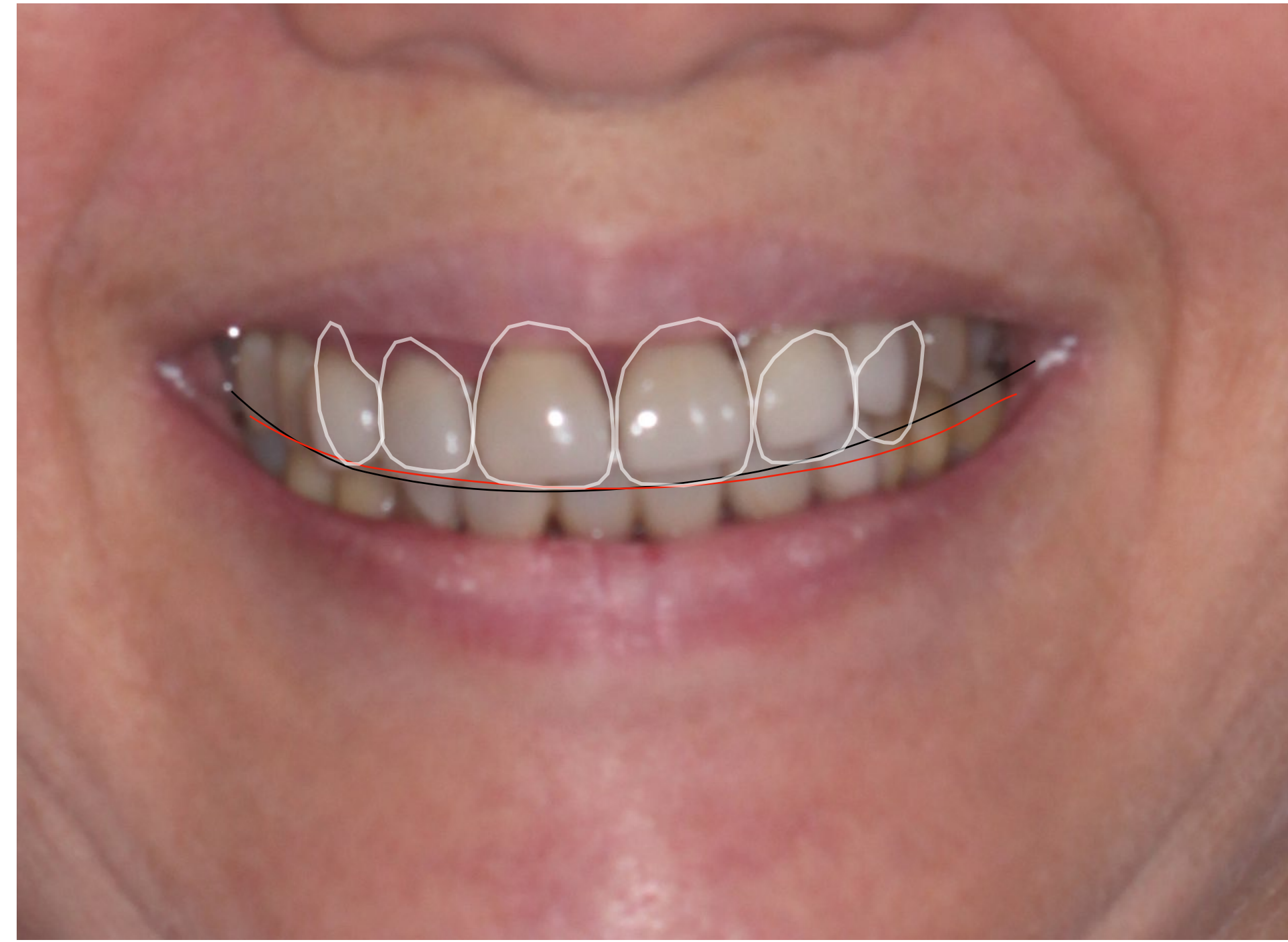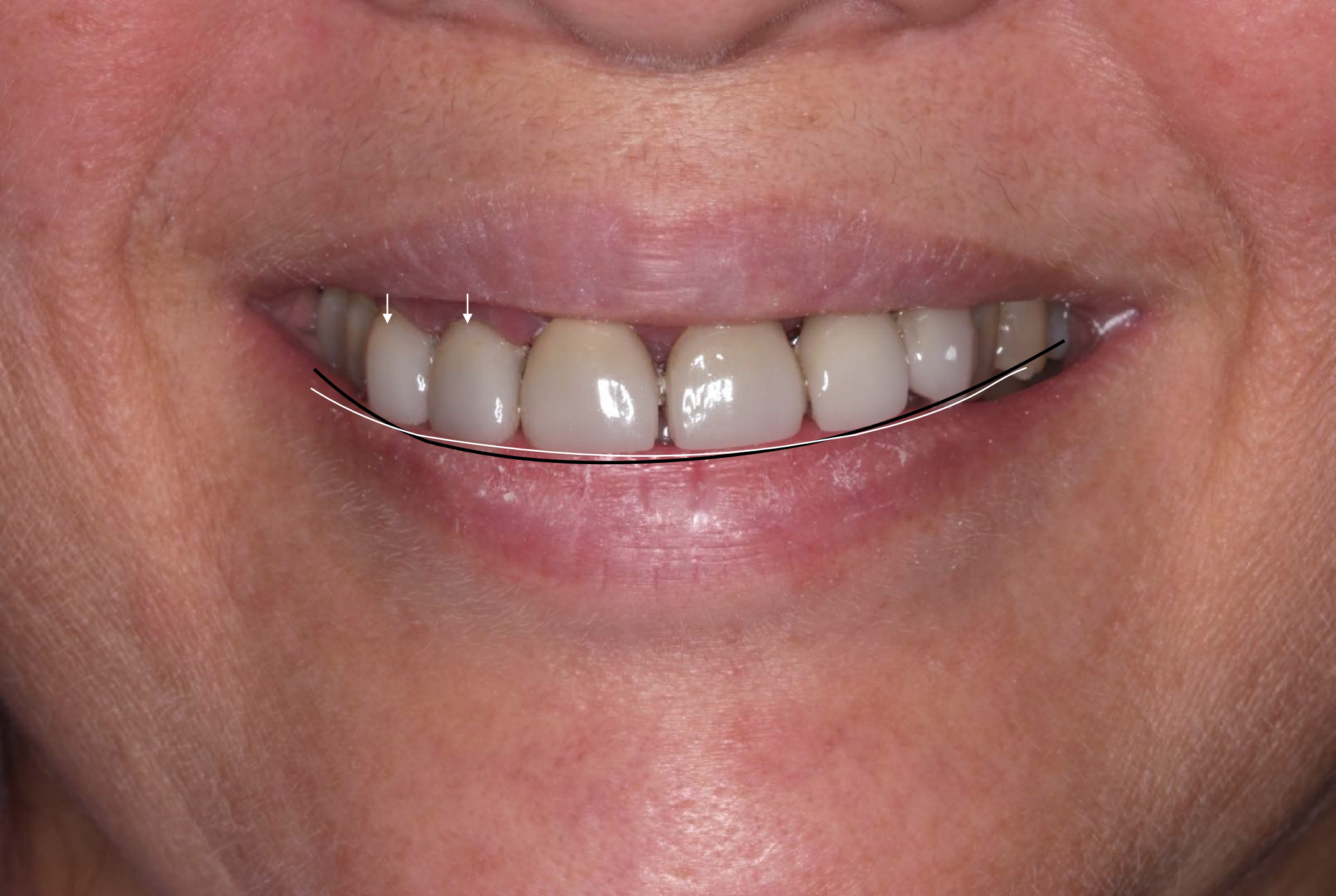the left side 21,22,23 the incisal plane is moving up gingival and less gingival display



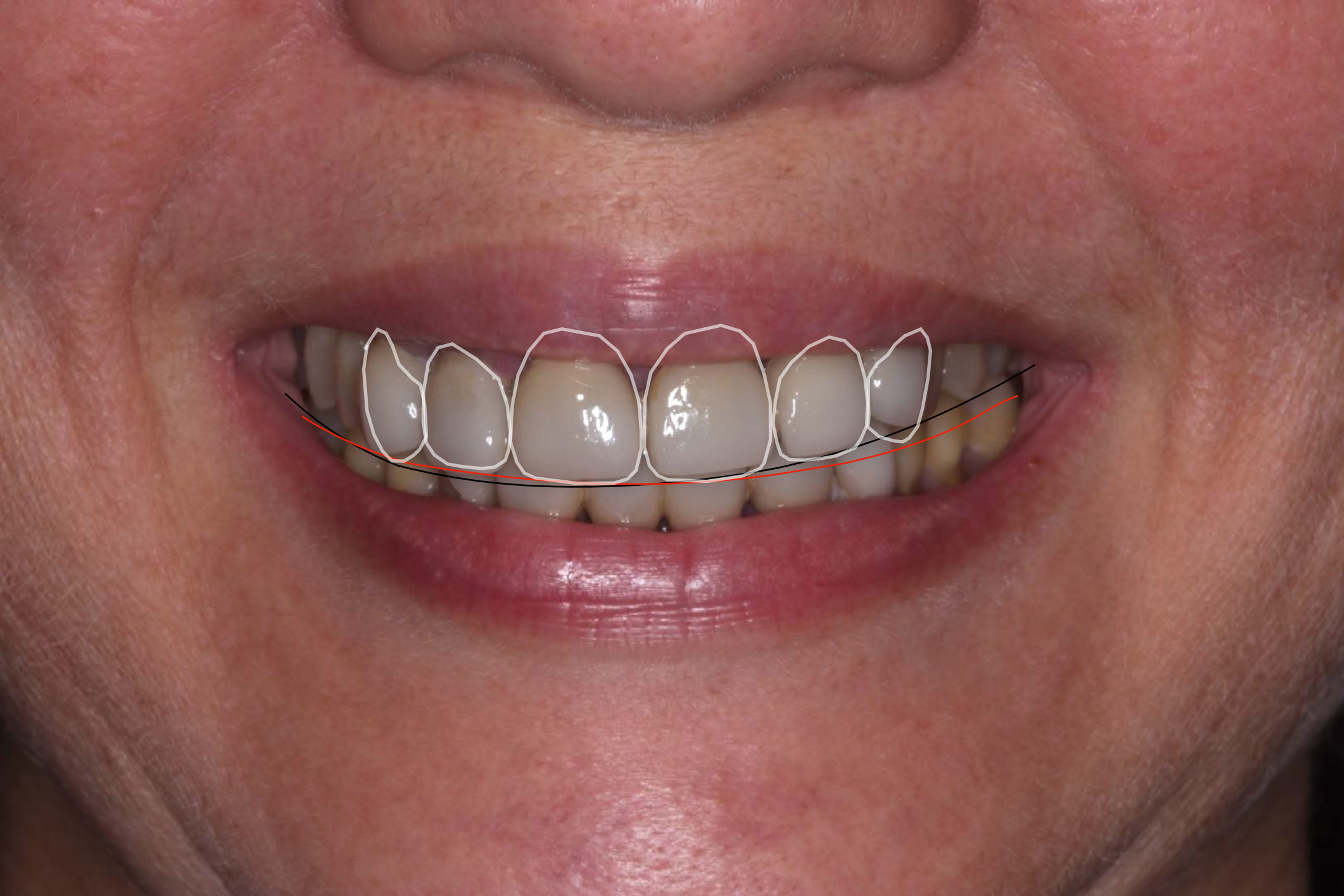
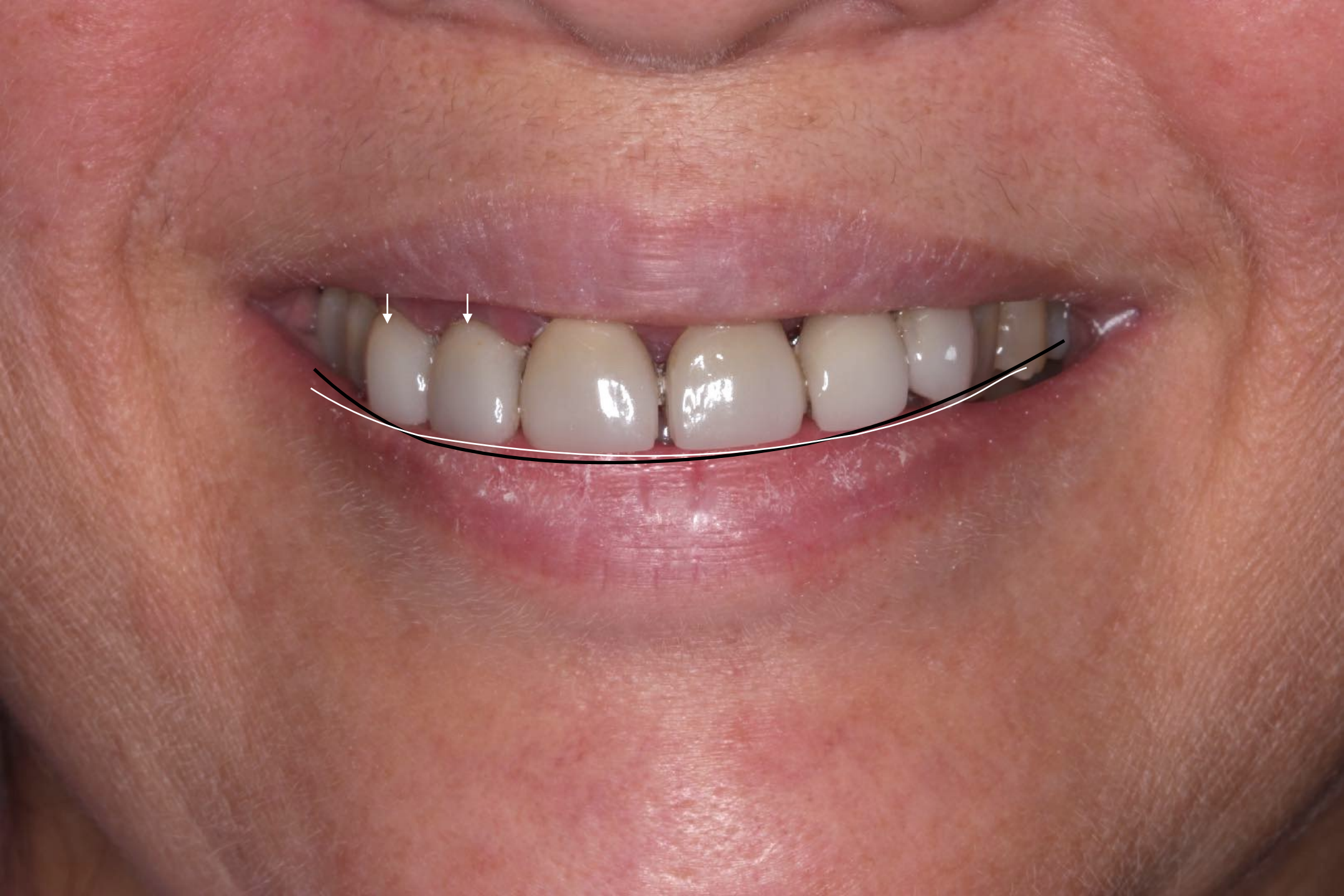




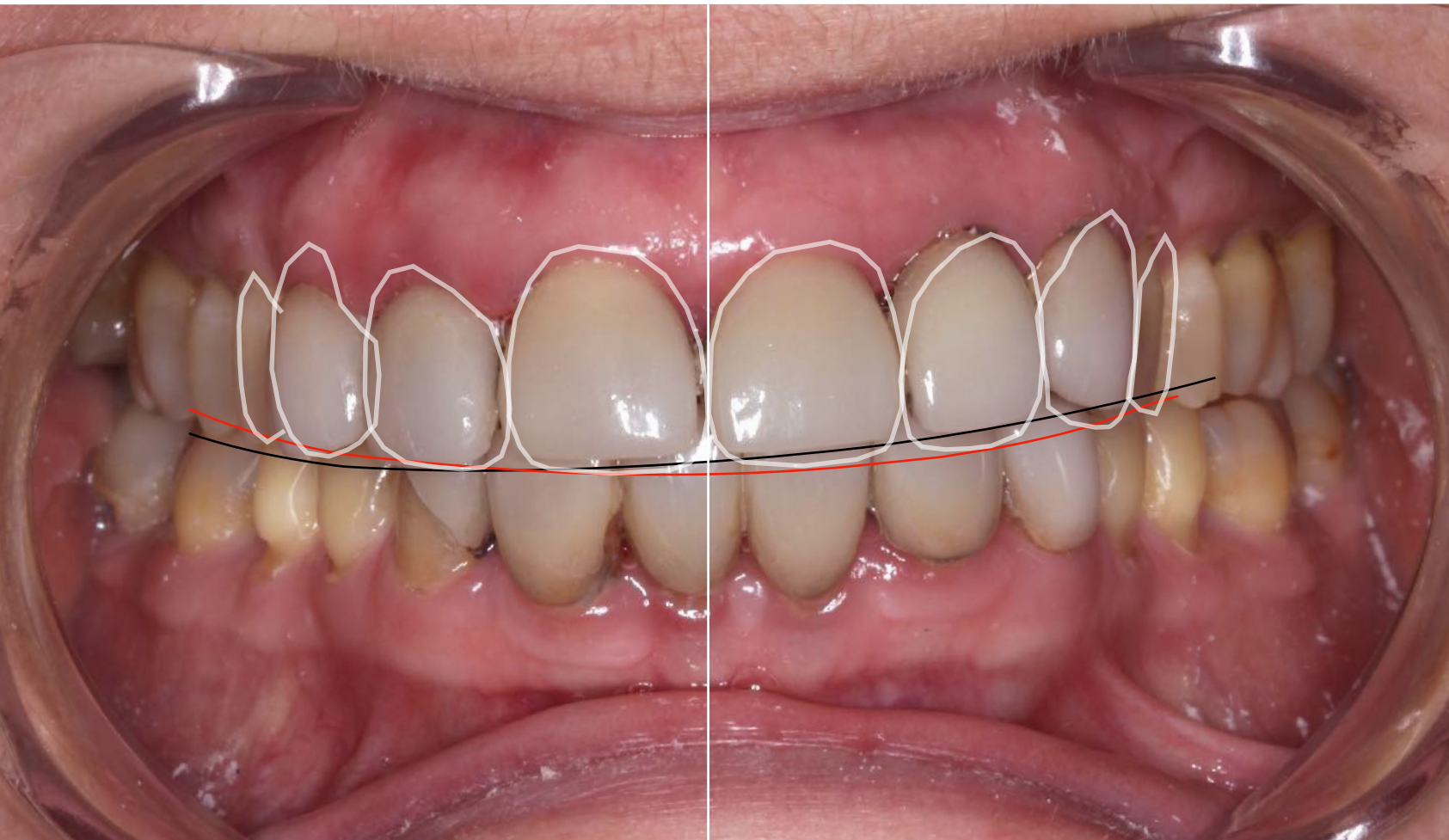








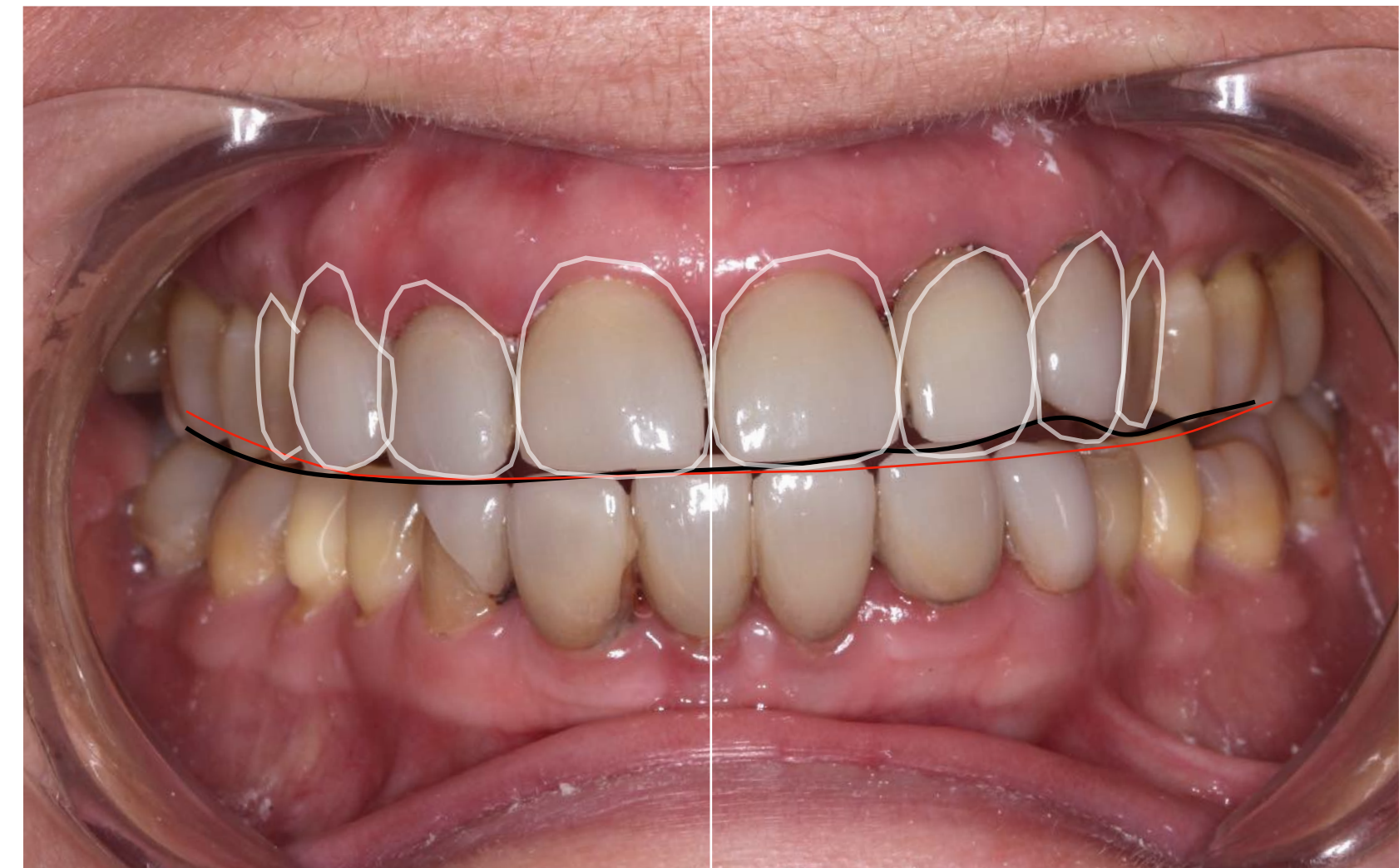
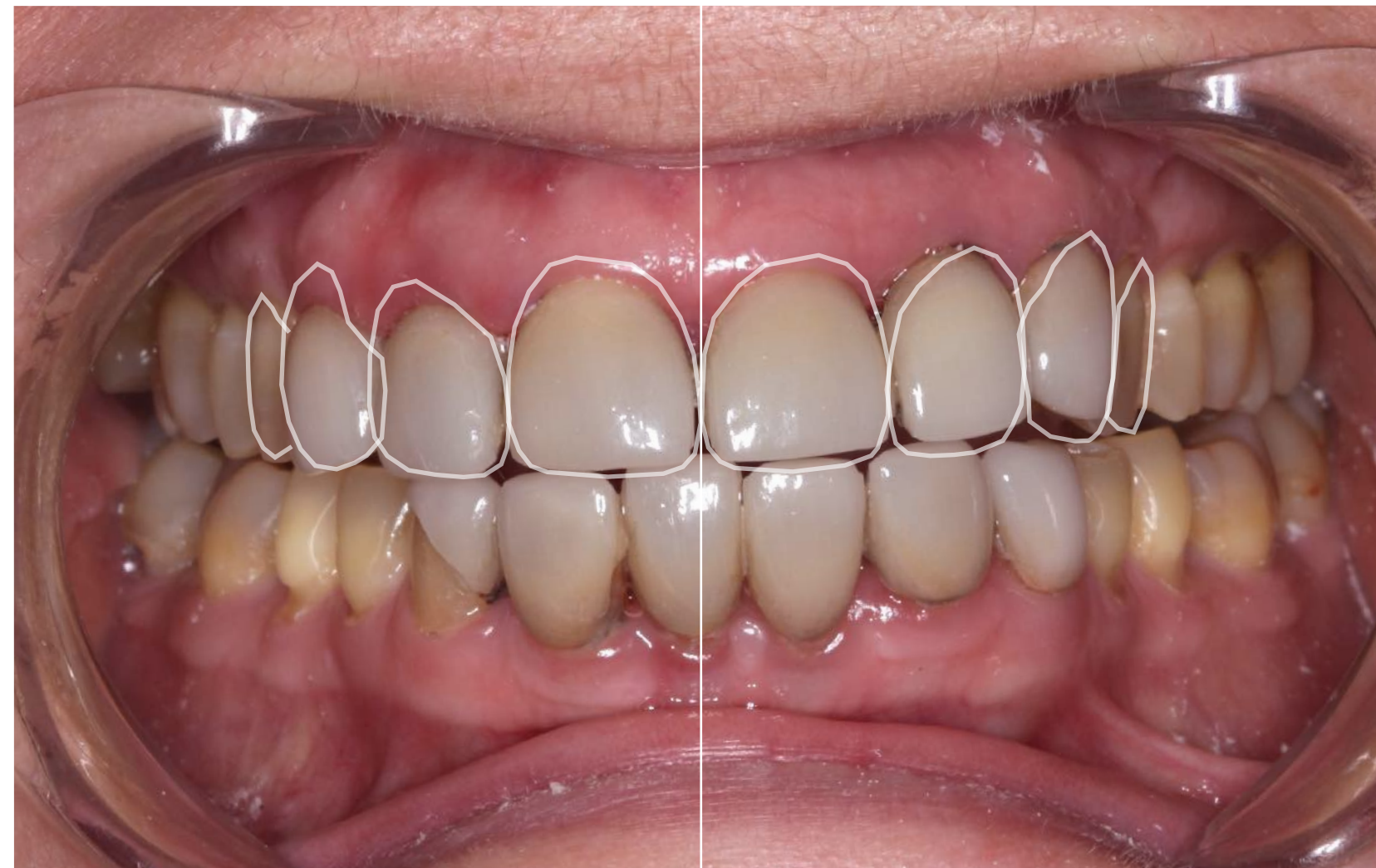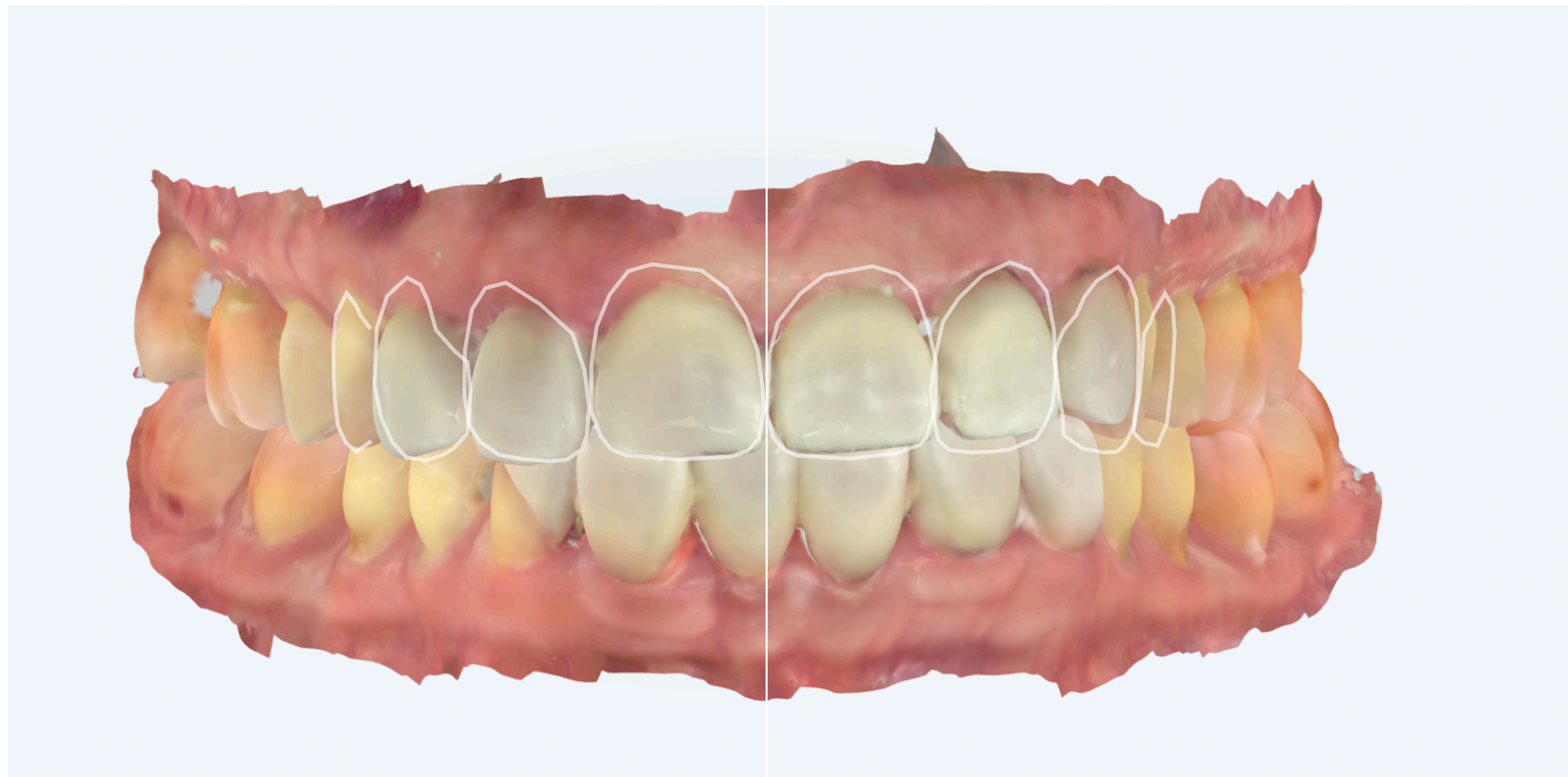the right side 13,12,11, the incisal plane is lower more occlusal, and there is more gingival display

the left side 21,22,23 the incisal plane is moving up gingival and less gingival display

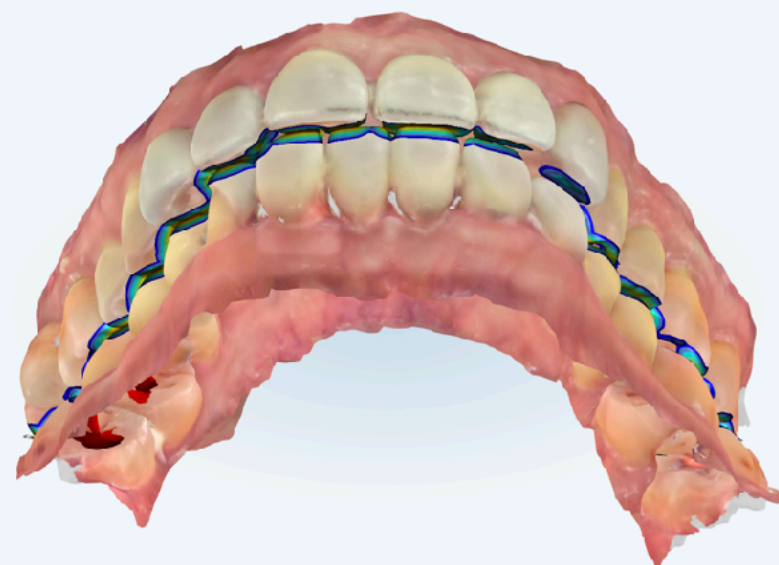
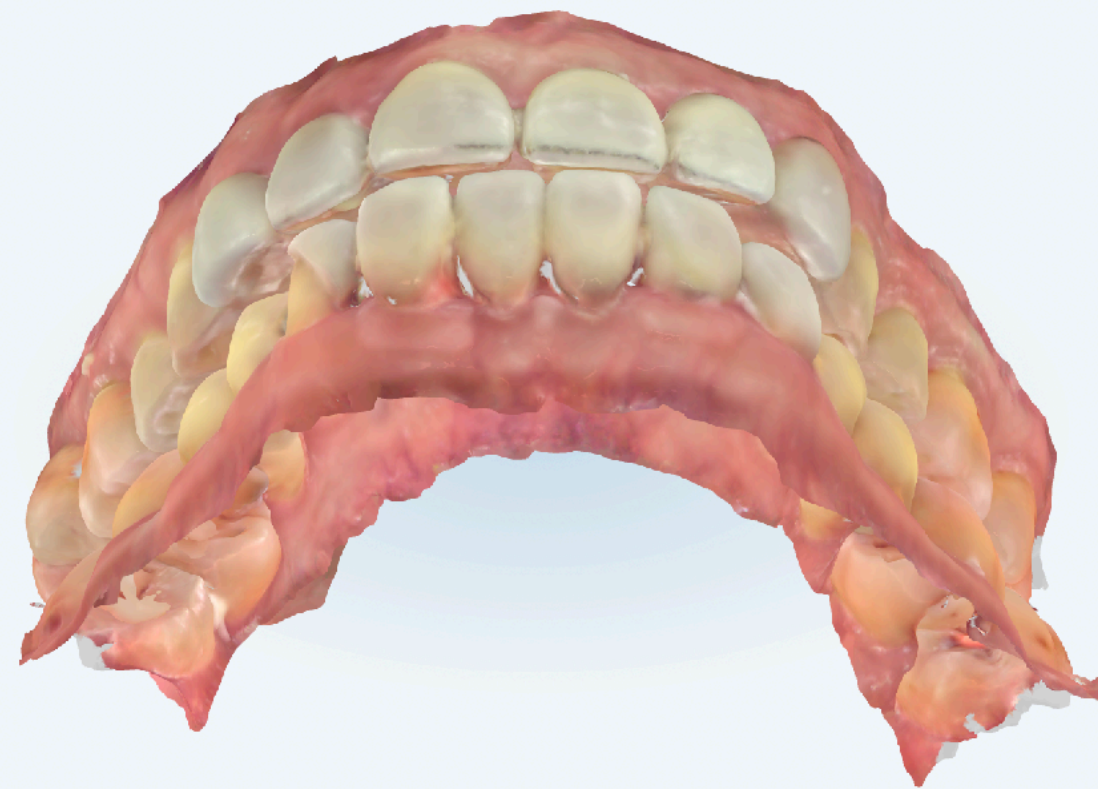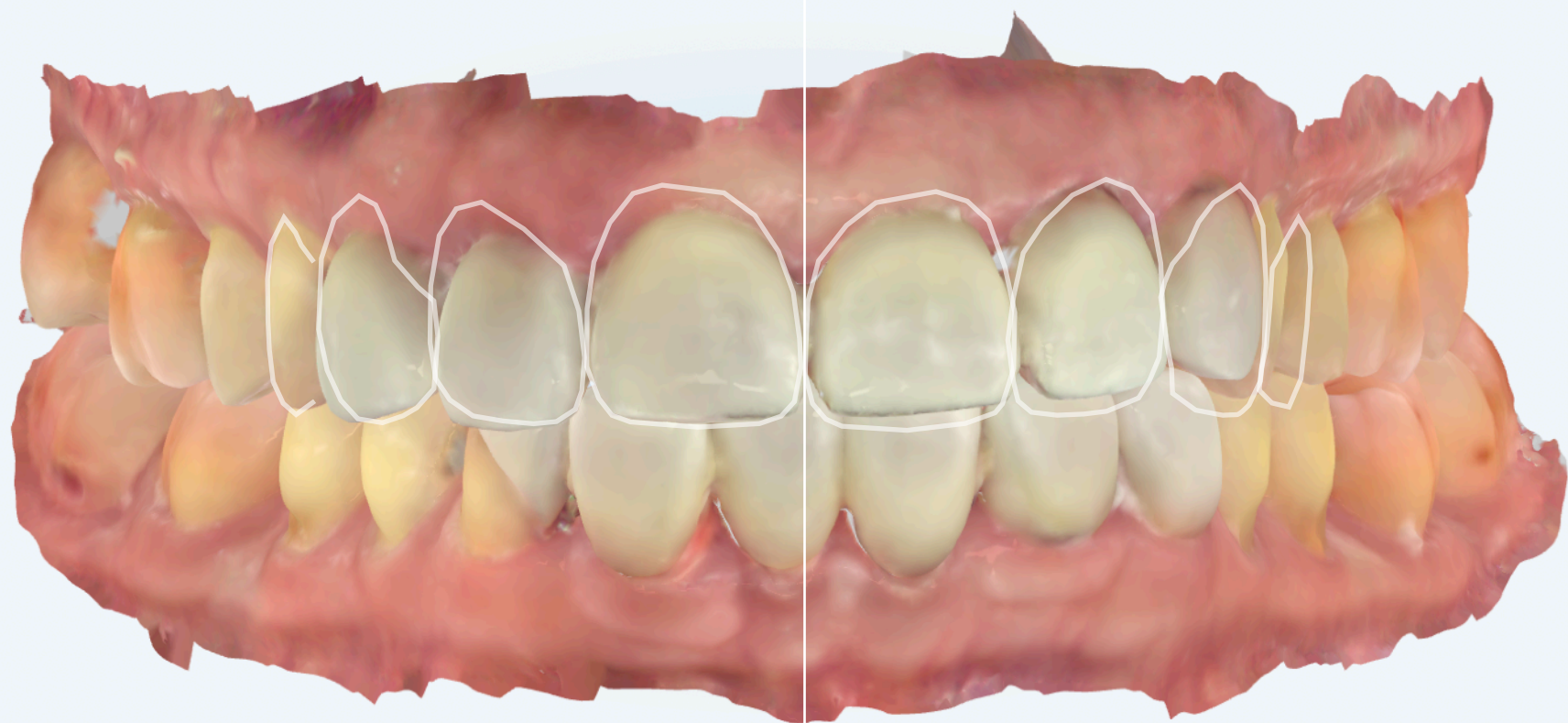
black is plane of current edge  
red is proposed incisal plane



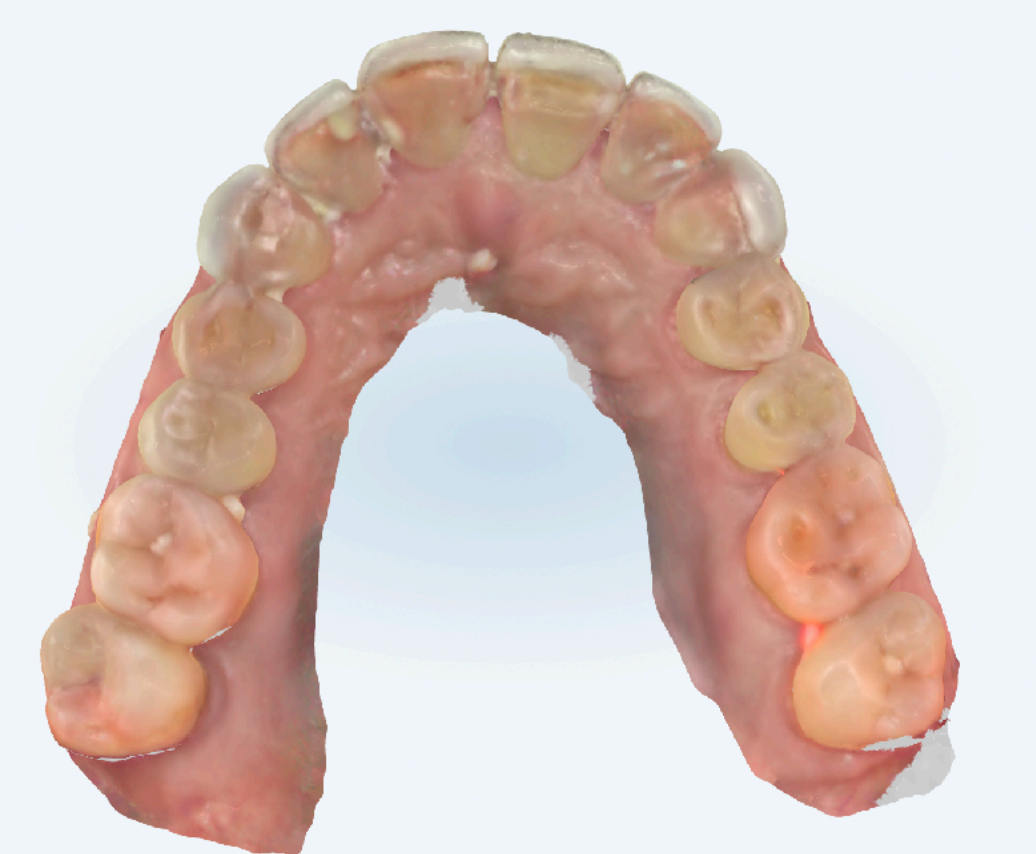



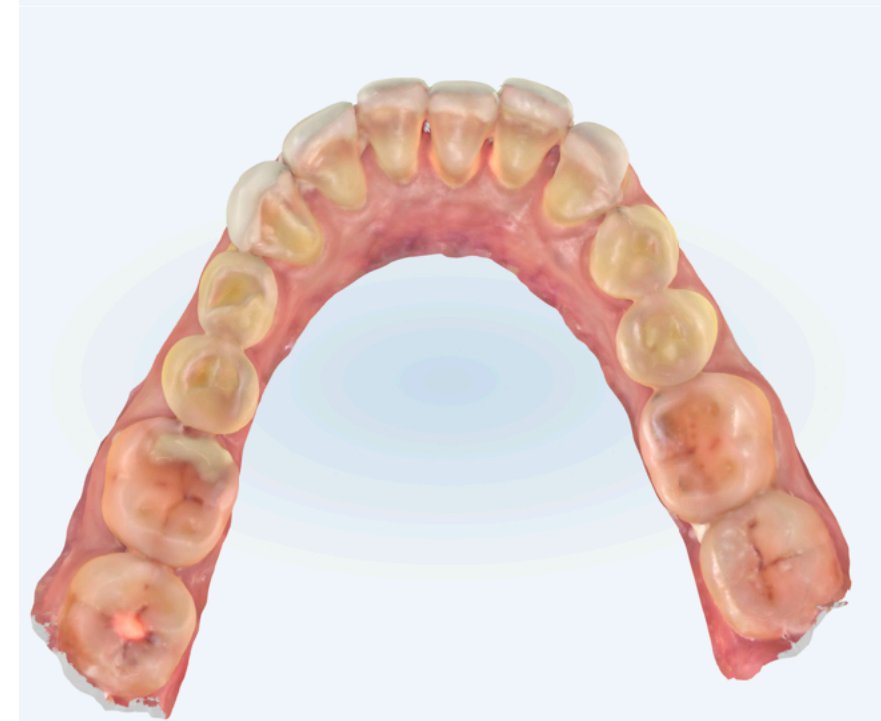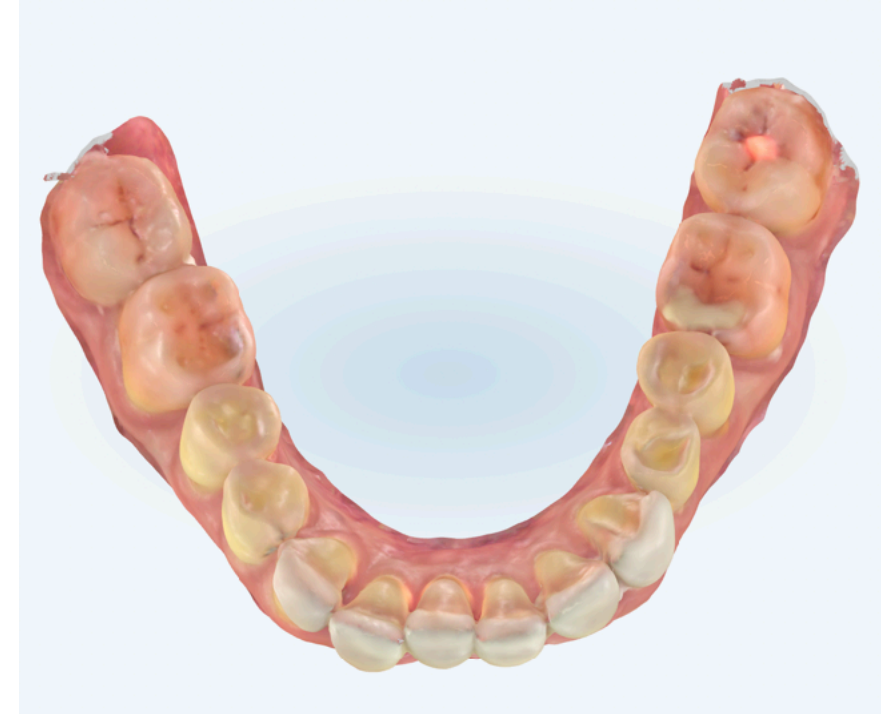
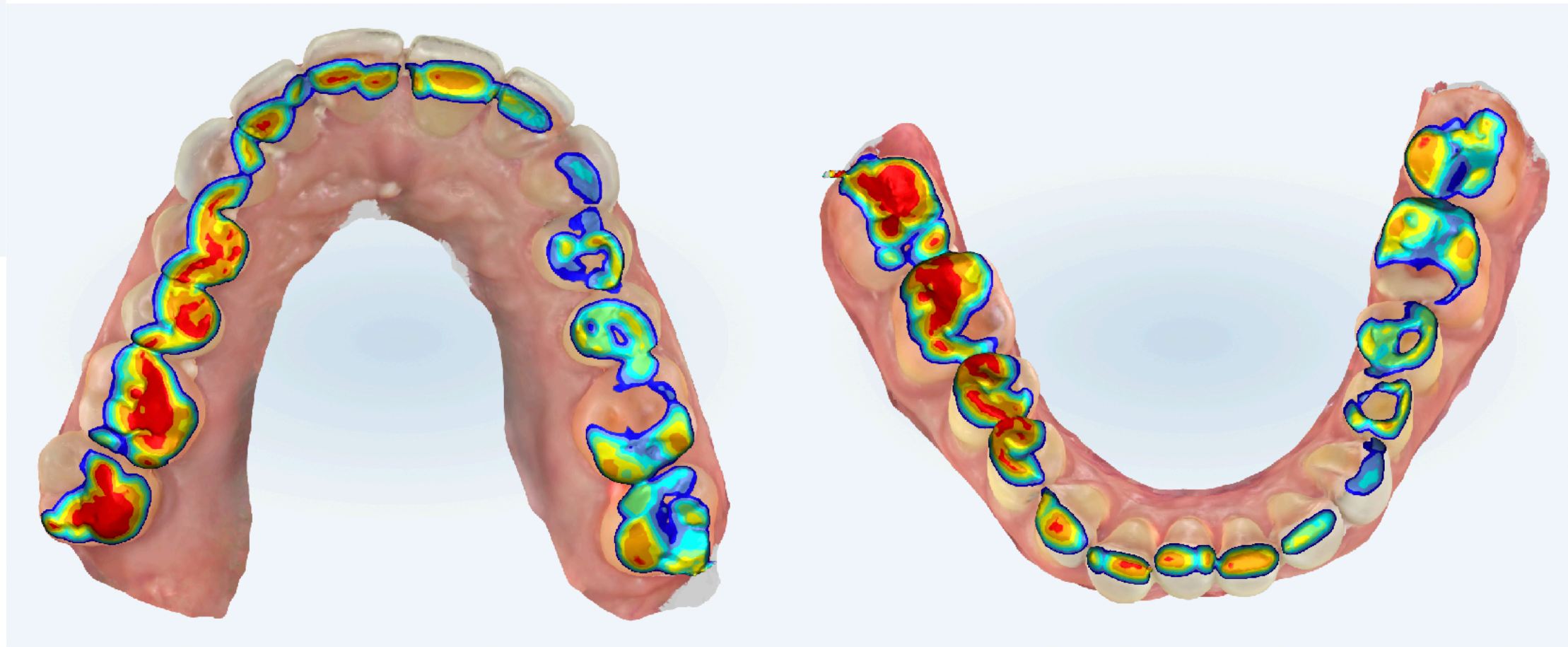






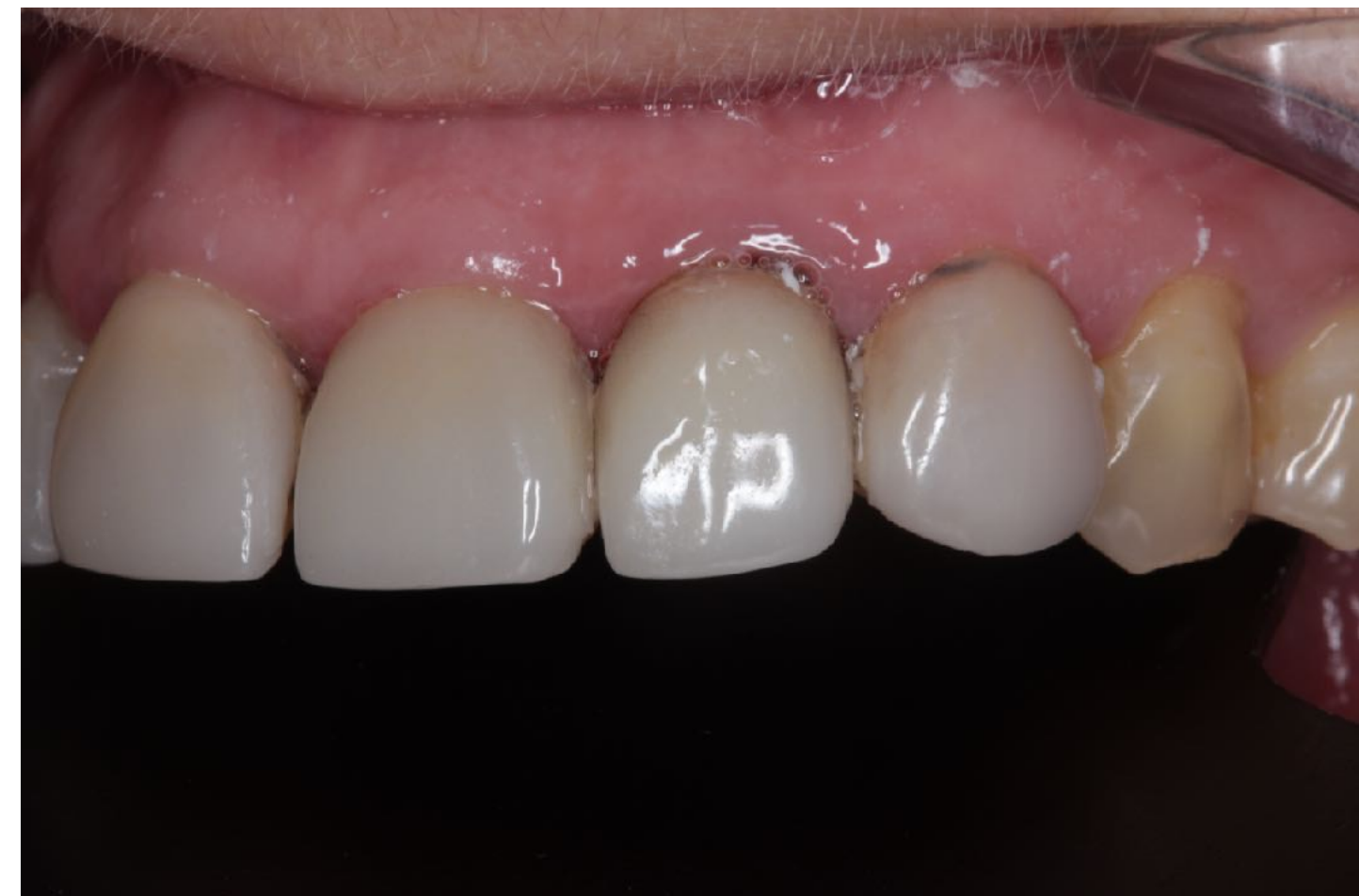
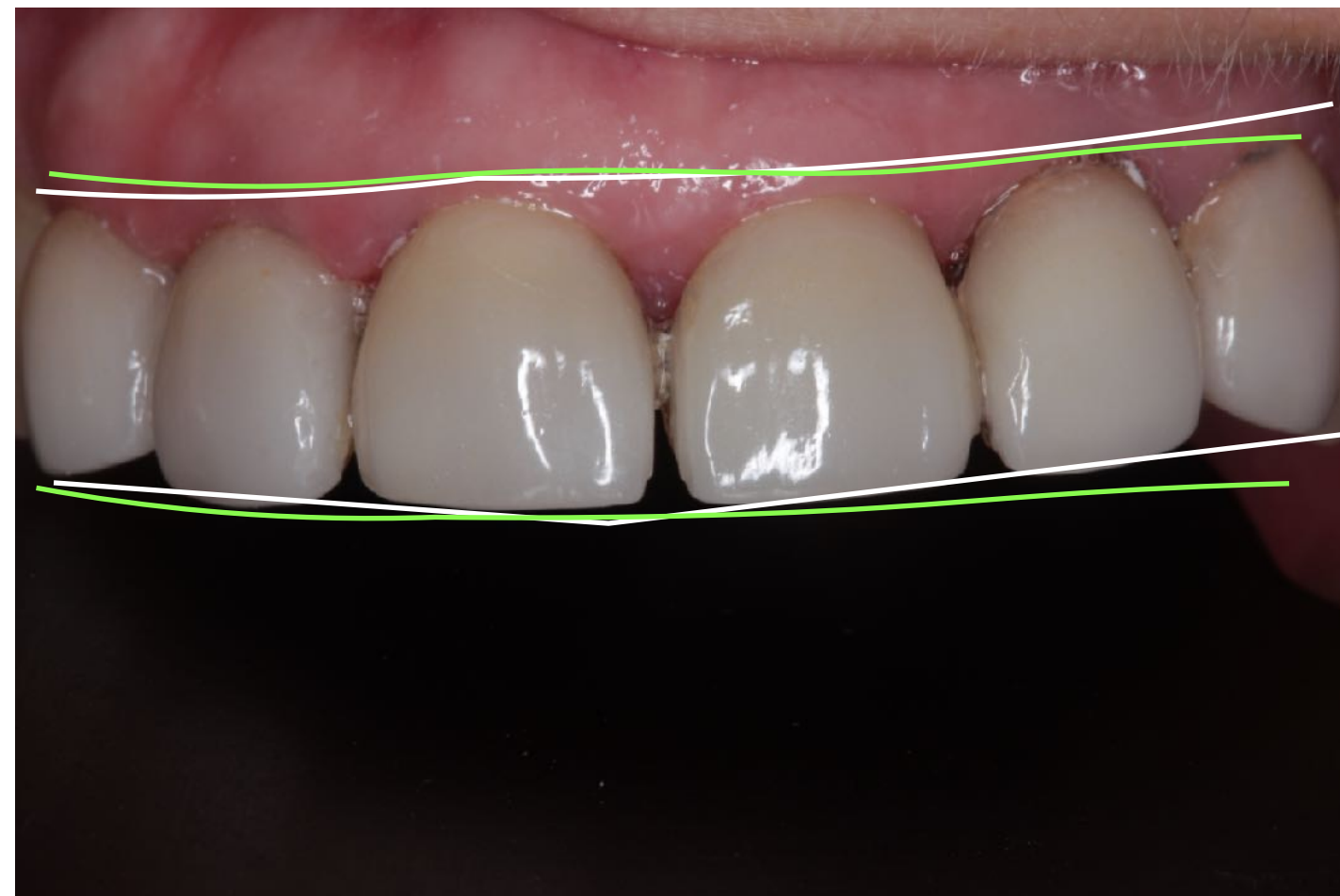
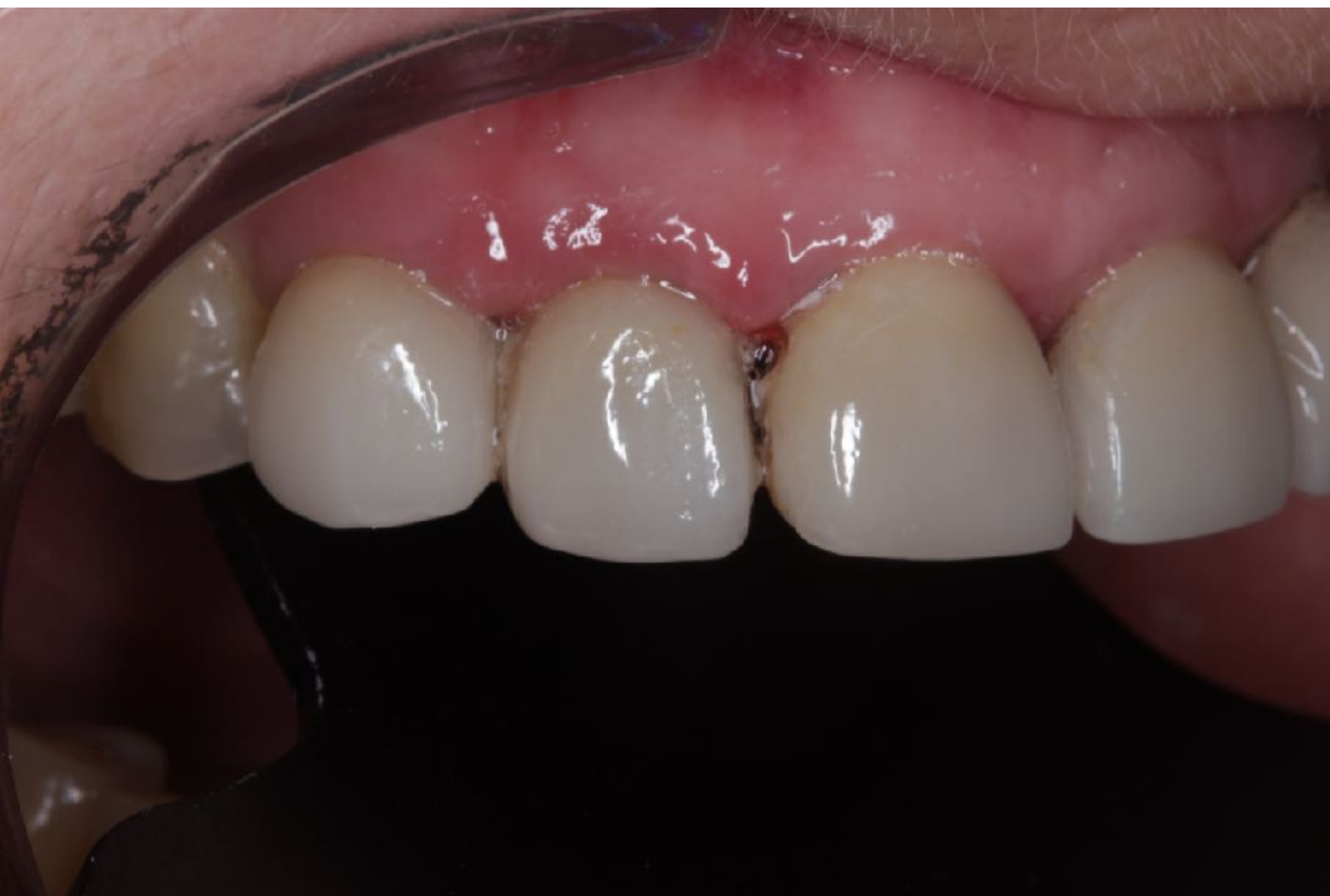The occlusal contacts. The left has lighter contacts on the 22,23 so can be brought down more



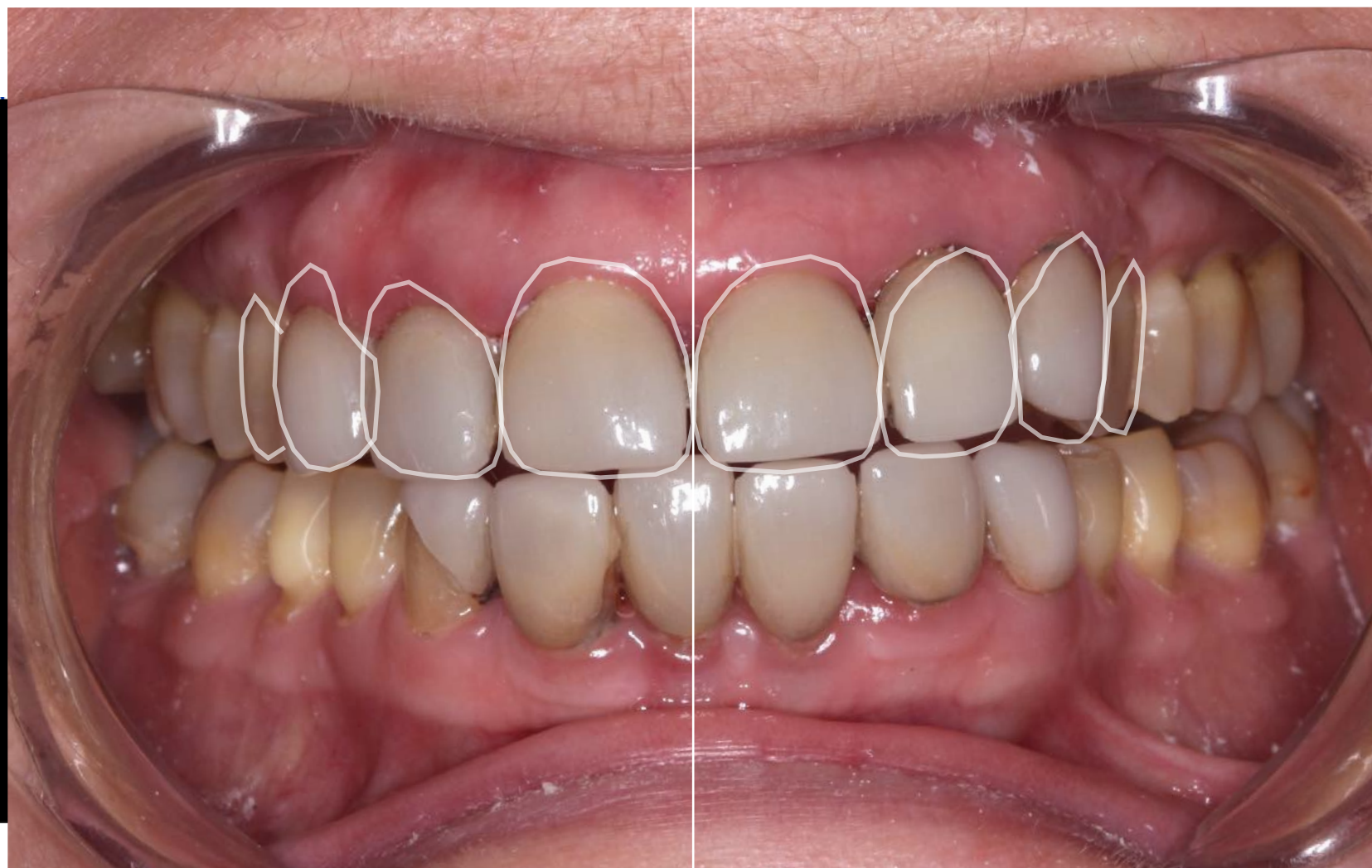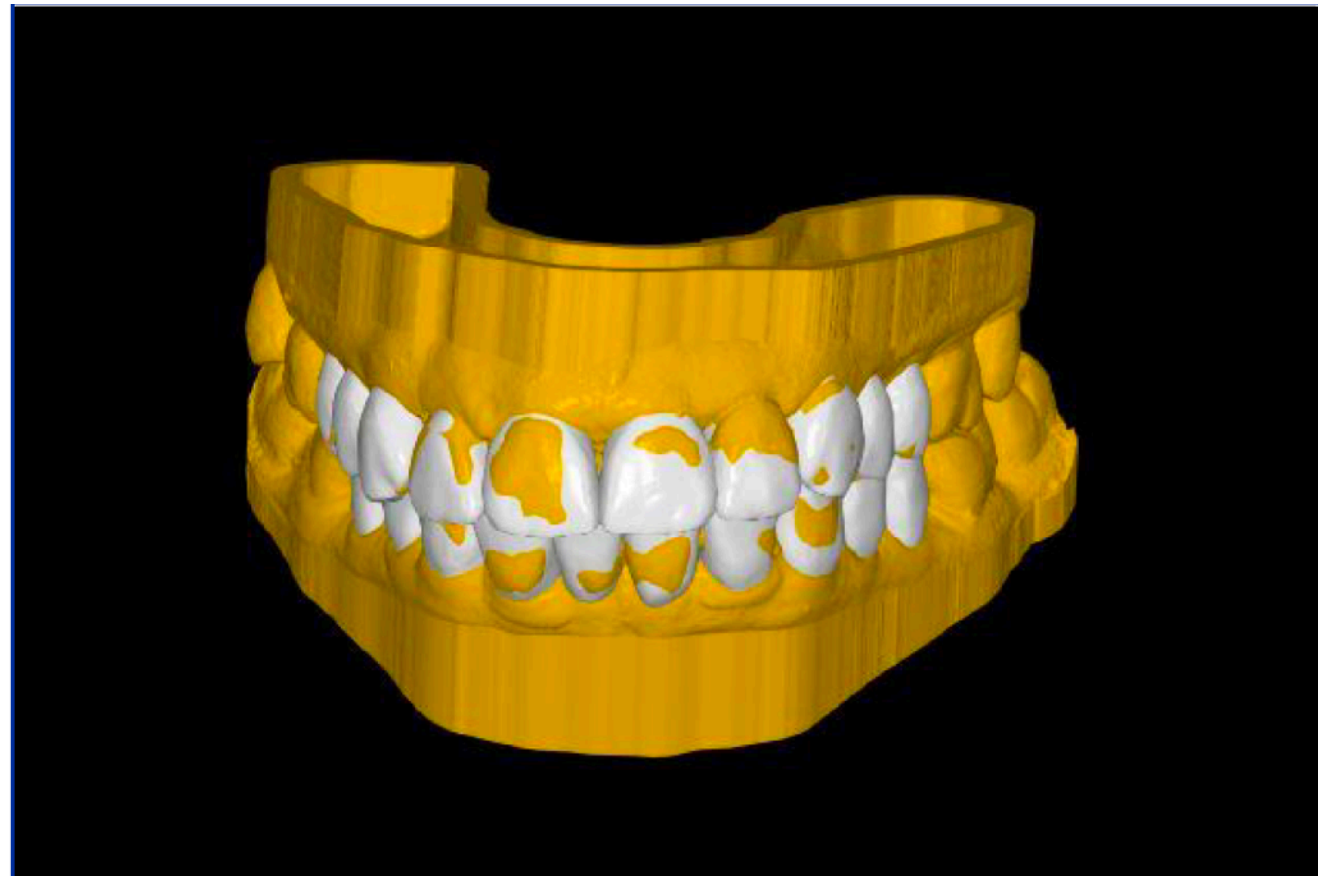
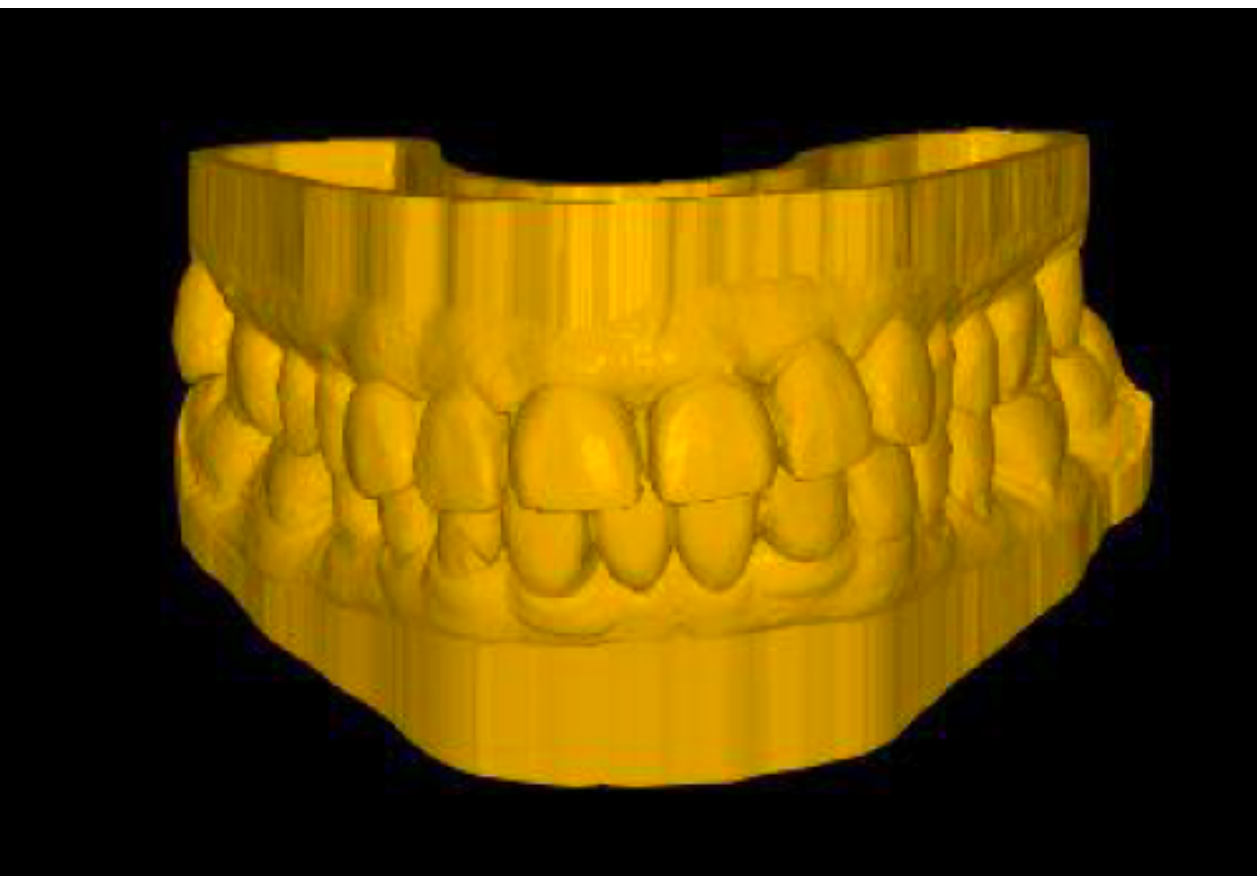




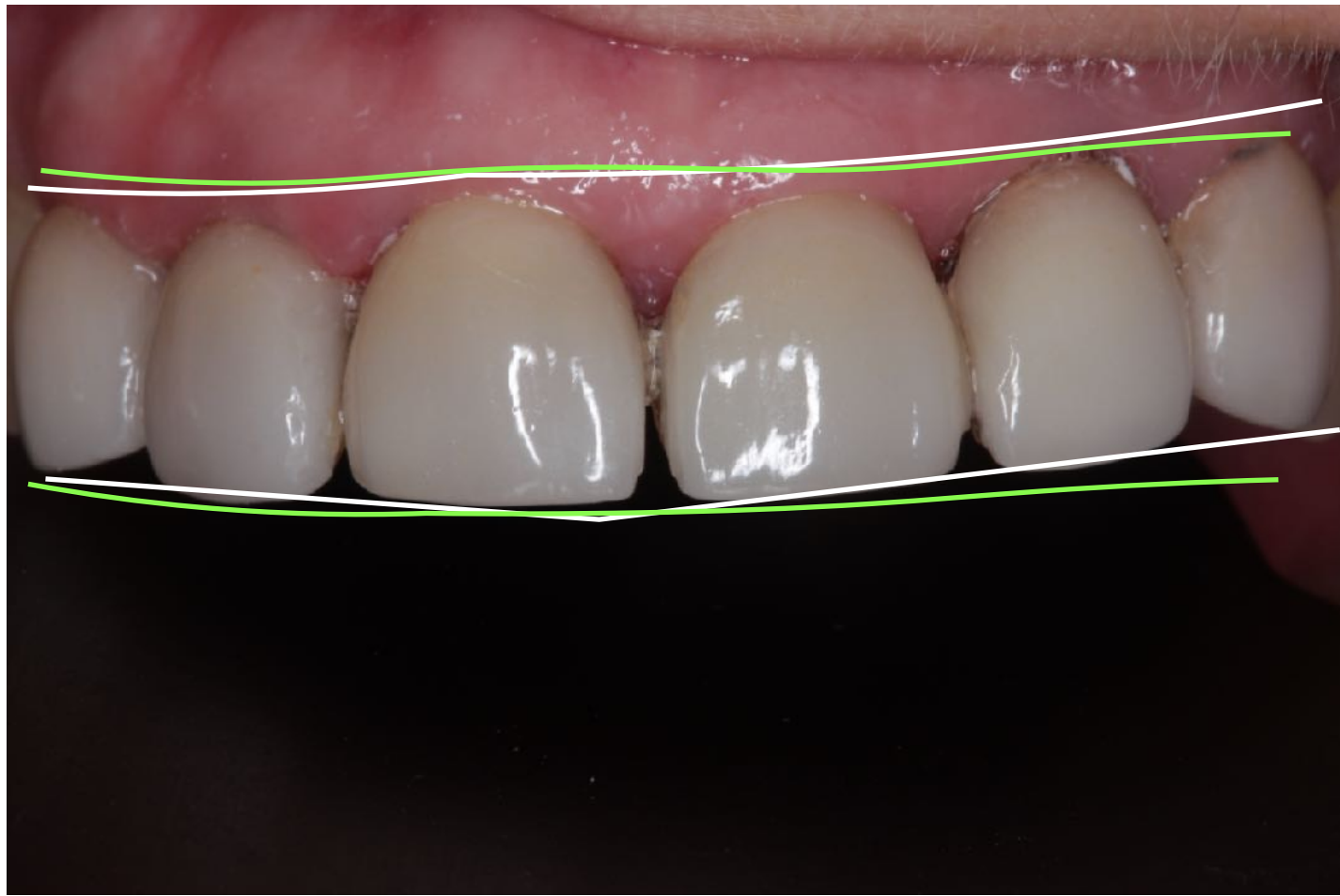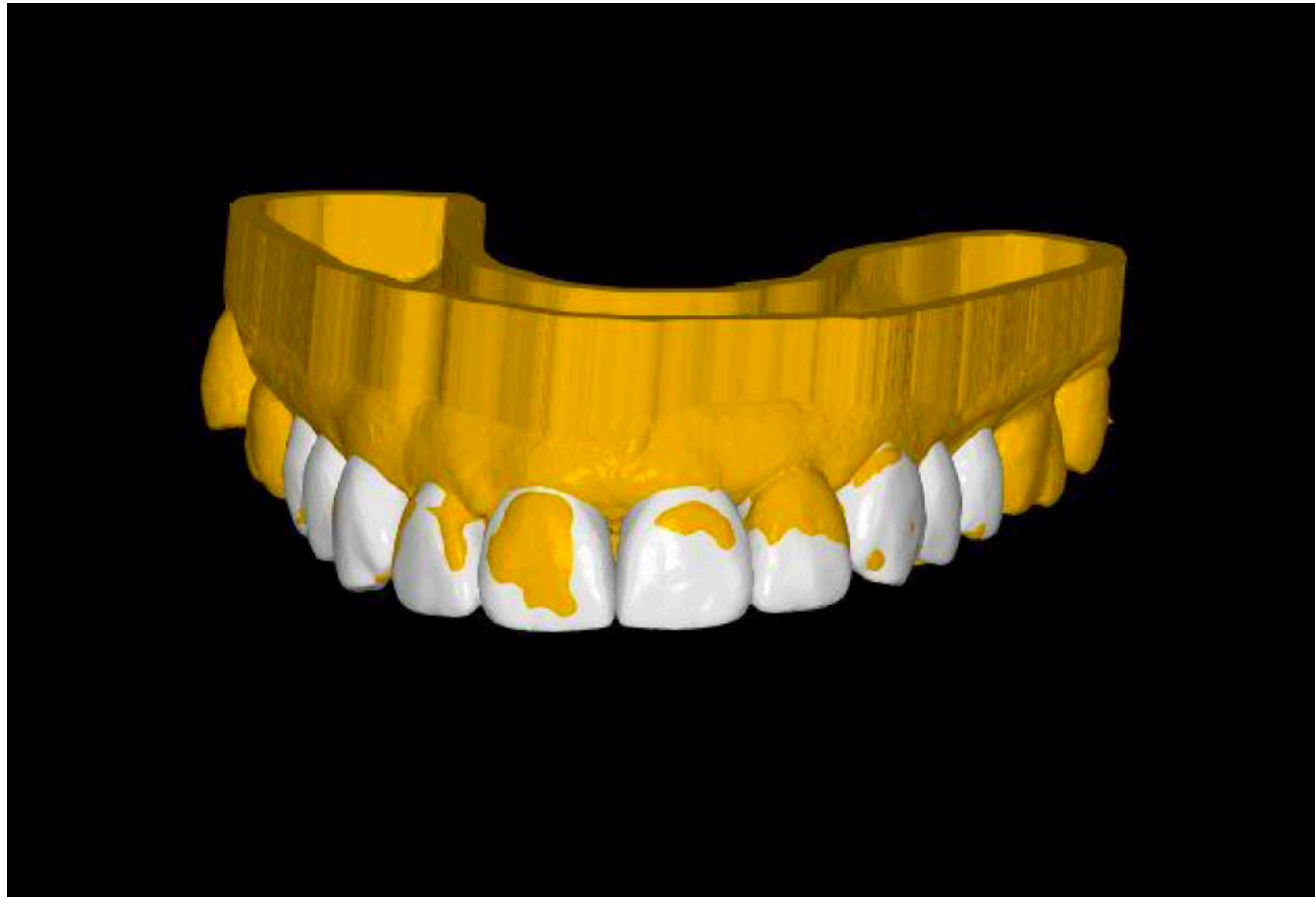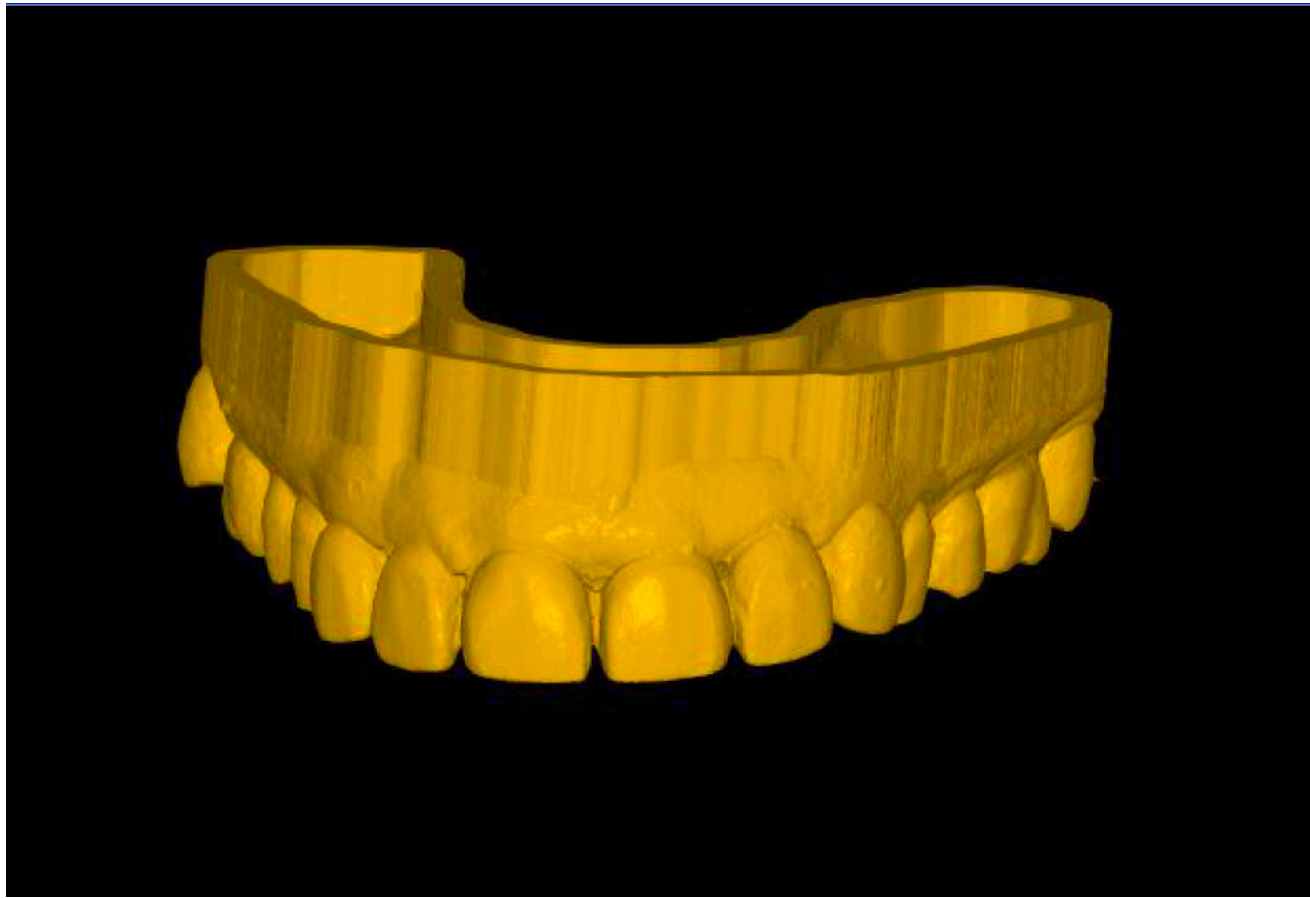




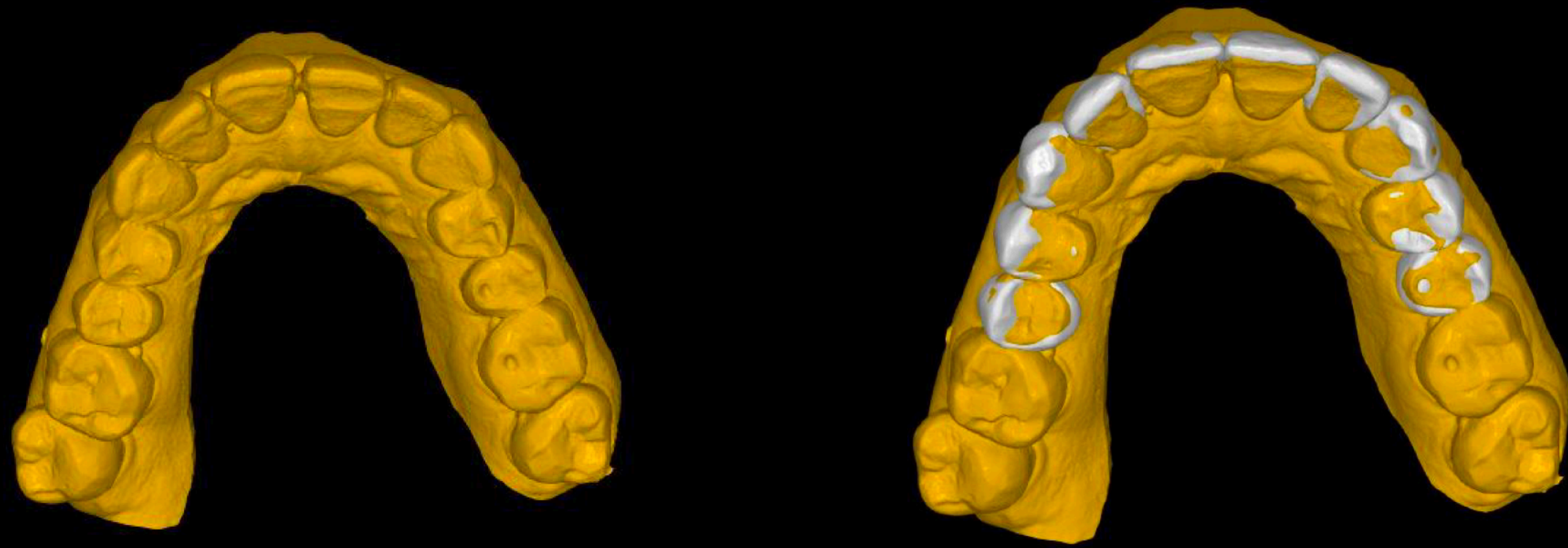




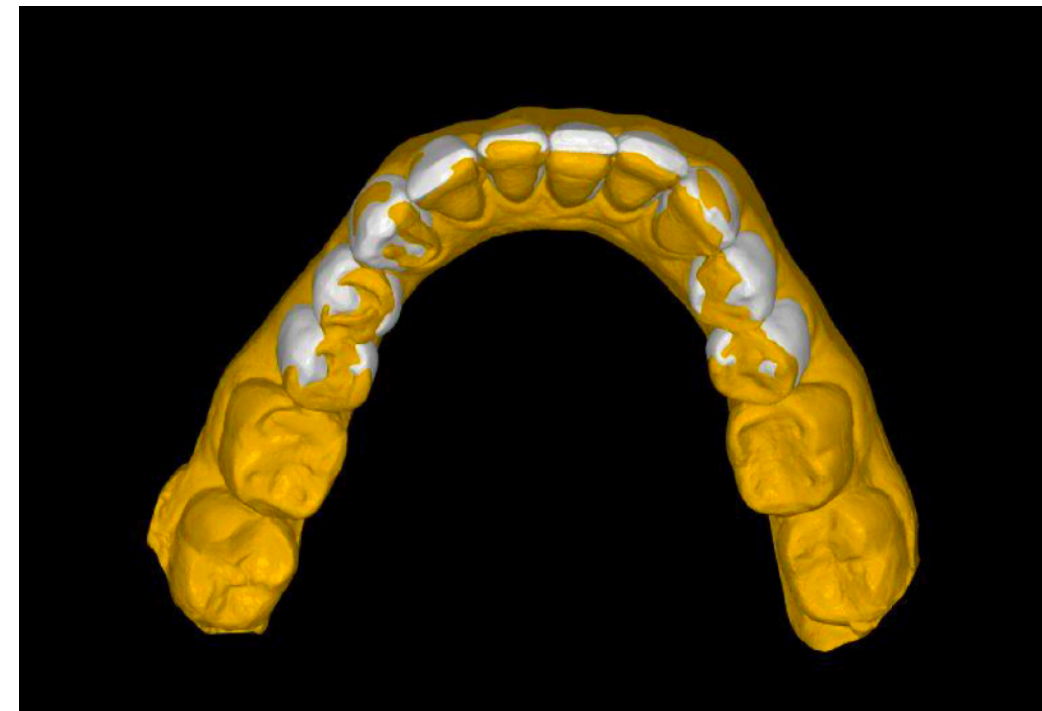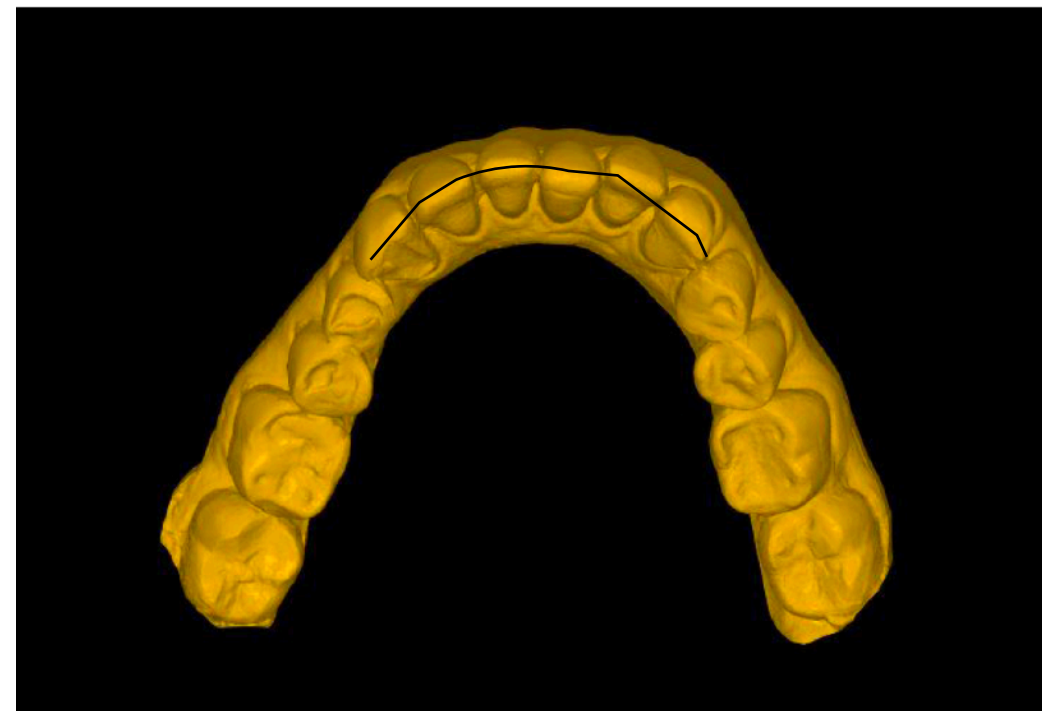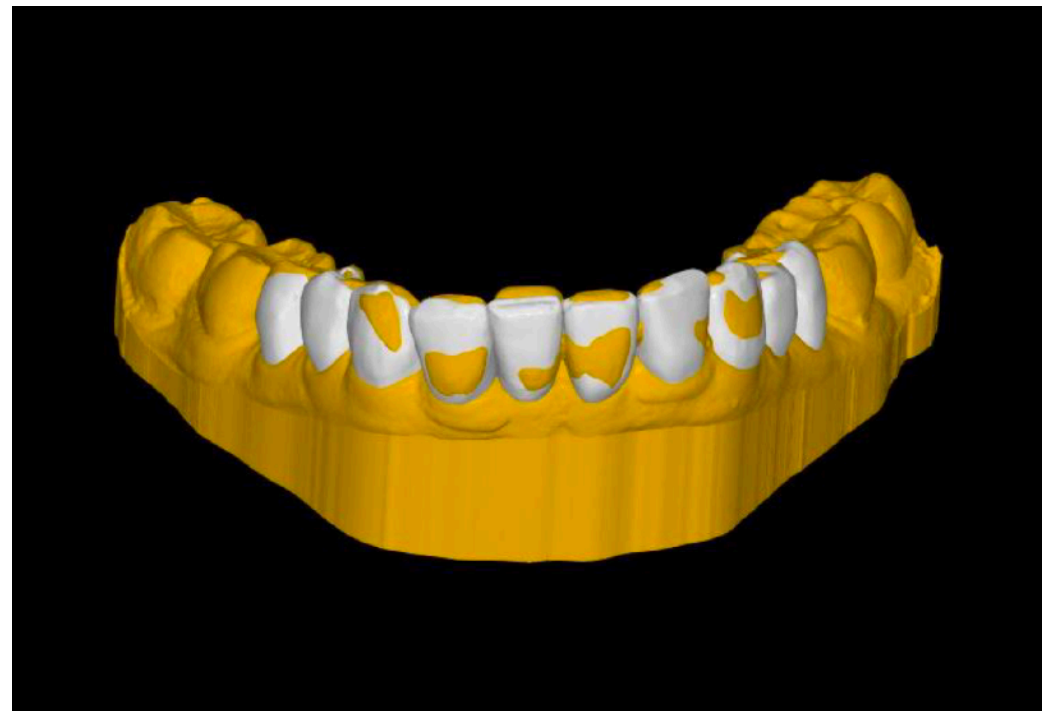
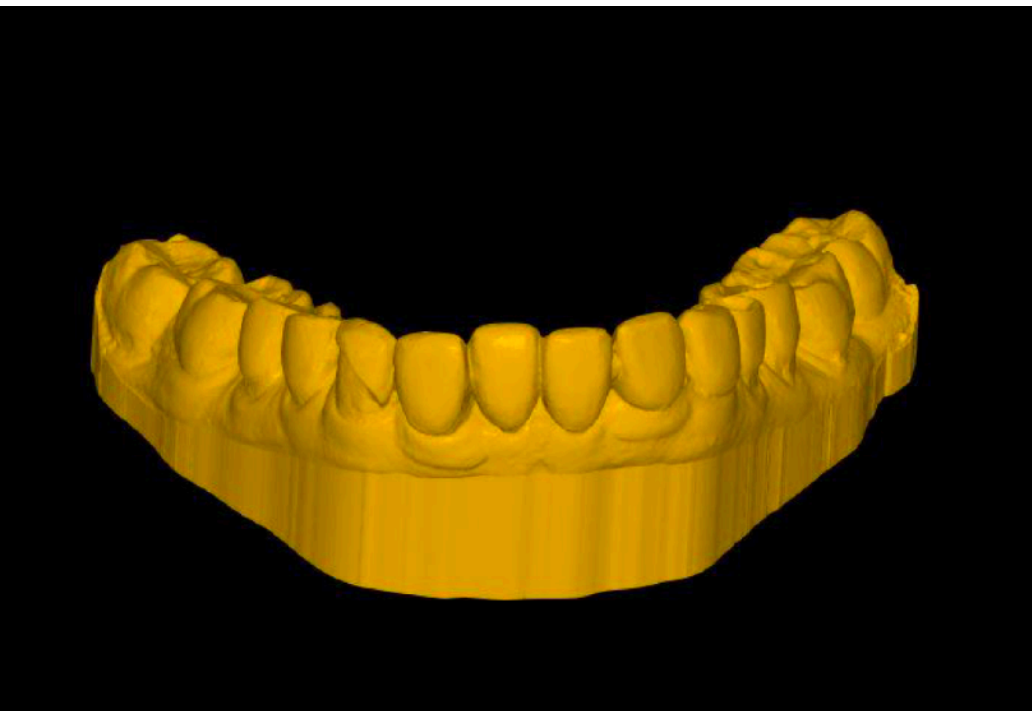














The teeth are too far labial. This will constrict the anterior envelop. Decrease all the bulk on the labial of the teeth and just even out the level.

